

Surgical management of intraosseous compound odontome preserving permanent incisors - report of two cases

*Juneja S, *Verma KG, ** Singh N, *Jindal S

*Department of Pediatric & Preventive Dentistry, Surendra Dental College & Research Institute
H.H. Gardens, Power House Road, Sri Ganganagar

**Department of Oral Pathology, Surendra Dental College and Hospital
Sriganganagar, Rajasthan, India.

*Correspondence: Juneja S

Email: drsuruchijuneja@gmail.com

Abstract

Odontomas are considered to be hamartomatous malformations rather than tumours. Compound odontomas are mostly found in anterior maxilla and complex odontomas are more prevalent in posterior mandible. Although the pathology is benign, early intervention is required to avoid the subsequent complications and ensure a better prognosis. Two case reports are presented where compound odontomas were associated with impacted teeth. In the first case, an unusually giant odontome caused impaction of both central and lateral incisor. Combined surgical and orthodontic treatment was required for eruption of central incisor whereas lateral incisor erupted after surgical exposure. In the second case surgical removal of the odontome and exposure of the incisal edge led to eruption of the impacted incisor.

Key words: compound odontome, anterior maxilla, impacted incisor

Introduction

Odontomas are developmental anomalies which result from the growth of completely differentiated epithelial and mesenchymal cells giving rise to ameloblasts and odontoblasts. These tumors are composed of enamel and dentin but they can also have variable amounts of cementum and pulp tissue⁽¹⁾. Compound odontoma develops when the deposition of enamel and dentin results in structures which are anatomically similar to normal teeth. Random proliferation of dental tissues to form irregular calcified masses bearing no resemblance to tooth results in complex odontoma. Compound odontomas appear more frequently (9-37%) than complex odontomas (5-30%)⁽²⁾. These odontogenic tumors can be found anywhere in the dental arches⁽¹⁾. The odontomas in the anterior segment of the jaws are mainly compound composite in type (61%), whereas majority in the posterior segment are complex composite in type (34%)⁽³⁾.

The etiology behind odontomes remains unclear. Numerous pathological conditions, like local trauma, inflammatory and /or infectious processes, mature ameloblasts, cell rests of serres (dental lamina remnants) or due to hereditary anomalies (Gardner's syndrome, Hermanns syndrome), odontoblastic hyperactivity, alterations in the genetic component responsible for controlling dental development have been implicated⁽⁴⁾.

The tumour has a limited growth potential and is not aggressive. However, early diagnosis is very important so that complications in dental arch development and occlusion, including esthetic problems are avoided⁽⁵⁾. Two cases of compound odontome associated with impacted permanent teeth are presented here.

Case Report 1

A 12 year old female patient reported to the Department of Pedodontics with a chief complaint of missing left upper permanent incisor since 6 months. She gave a history of getting the deciduous predecessor extracted 6 months back from a private clinic. There was no history of trauma to orofacial region. Medical history and family history were non contributory. General physical examination revealed no systemic anomalies. Clinical examination revealed unerupted 21 and 22 associated with a hard painless swelling in the central incisor region with normal overlying mucosa (**Figure 1A**).

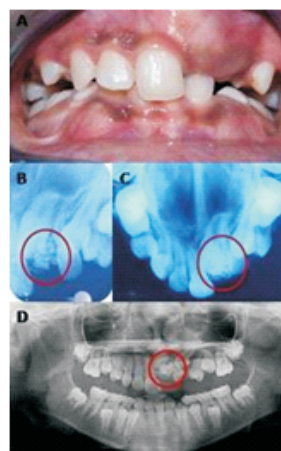


Figure 1. Case 1 - A. Preoperative intraoral photograph showing unerupted 21 and 22. B, C & D Intraoral periapical radiograph, occlusal radiograph and OPG depicting cluster of radio opaque masses

Radiographic examination revealed multiple opaque calcified masses overlying an impacted and dilacerated 21 as well as an impacted 22 (**Figures 1B, 1C, 1D**). Clark's technique suggested labial orientation of the calcified masses. The provisional diagnosis of compound odontome was made. The hematological investigations, ultrasound and CT scan were performed. No systemic abnormality was observed, confirming the final diagnosis of compound odontome.

Treatment

Surgical enucleation of the odontomas was planned. Informed consent was obtained from parents. The procedure was carried out under local anaesthesia, without any premedication. Incision was carried out and a mucoperiosteal flap was raised. Bone cutting on labial aspect was done as the calcified masses could not be approached from crest of the alveolar ridge. Multiple calcified structures were removed using a periosteal elevator and were immersed in saline and sent for histopathological examination. The masses were unusual in number (18-20) and mosaic collection of both particulate structures and denticles (**Figure 5A**).

Following their removal, curettage was done and the enucleated cavity was irrigated with saline to ensure no remnants. An intraoral periapical radiograph was taken before the closure of flap to ascertain complete enucleation of the lesion (**Figure 2B**). The flap was repositioned and sutured with 3-0 silk sutures. Prophylactic antibiotic and analgesic were prescribed. Postoperative oral and written instructions regarding maintenance of oral hygiene, ingestion of soft and cold meals and management of pain were given to the patient's parents. Sutures were removed on 7th postoperative day when complete healing was observed. Postoperative occlusal radiograph and OPG were taken (**Figures 2C, 2D**).

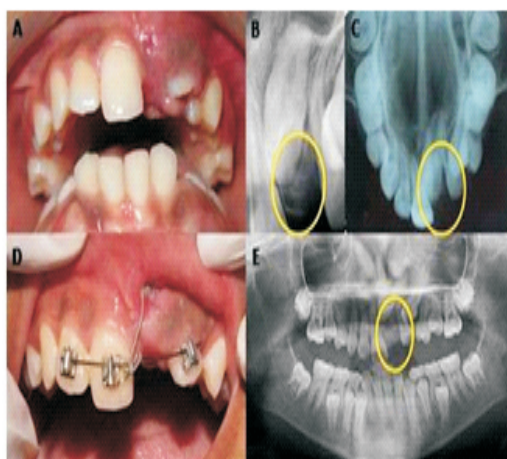


Figure 2. A. Intraoral photograph after one month showing erupting 22. B, C & E. IOPA, occlusal radiograph and OPG to ensure complete enucleation. D. Orthodontic traction after surgical exposure of 21

Histopathological examination at 40 X revealed the presence of enamel, dentin and pulp on decalcification (**Figures 5C, 5D**). One month later, 22 erupted while 21 still remained unerupted (**Figure 5A**). IOPA revealed no change in the position of 21. Hence, 21 were surgically exposed and Begg's bracket was bonded on the same. Traction was applied on the tooth using ligature wire engaged with 0.016 x 0.022 stainless steel arch wire. Orthodontic intervention is still in progress (**Figure 5D**).

Case Report 2

An 11 year old female patient presented with the chief complaint of missing left upper front tooth since 2 years. There was a history of deciduous tooth shedding 2 years back in the same region. Past medical history, dental and family history was not significant. No abnormality was detected on general physical and extraoral examination. On intraoral examination, 12 was clinically missing while the contralateral tooth was present (**Figure 3A**). A slight palatal elevation could be palpated in the edentulous region.

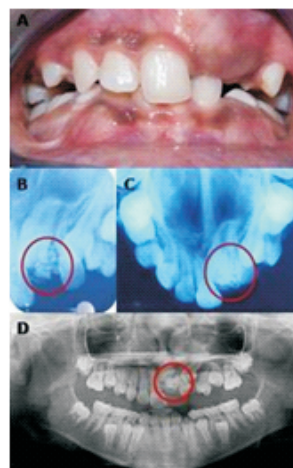


Figure 3. A. Intraoral photograph showing impacted 12. B, C & D. IOPA, occlusal radiograph and OPG revealing dense radiopaque structures overlying 12 suggesting compound odontome.

On radiographic examination (IOPA, occlusal radiograph and OPG), multiple opaque calcified structures in the mesioincisal region of 12 were evident (**Figure 3B, 3C, 3D**). To ascertain the labiolingual orientation of the calcified masses, IOPAs were taken using Clark's technique. Since the image of the structures moved opposite in relation to the tooth, it was concluded that they lie labial to 12. Hematological investigations, ultrasound and CT scan were required to rule out any systemic abnormalities. Based on the investigations and the clinical presentation, a provisional diagnosis of compound odontome was made.

Treatment

Surgical removal of the odontome was planned. Prior to the procedure, informed consent was obtained from parents. Under local anesthesia, incision was made and mucoperiosteal flap was raised from 13 to 11 by blunt dissection. The calcified masses were enucleated, immersed in formalin and sent for histopathological examination. The enucleated odontome consisted of three small particulate masses and a large mass which was formed of five fused denticles (**Figure 5B**). Incisal edge of 12 was exposed for facilitation of eruptive movement. The area was irrigated and curettage was done. An IOPA was taken before closure to ensure complete removal (**Figure 4B**). Flap was sutured with 3-0 silk sutures and postoperative instructions were given. Sutures were removed after one week and excellent wound healing was observed. Postoperative radiological investigations were done (**Figures 4C, 4D**). Ground sections of the specimen at 40X exhibited enamel, dentine and pulp space, thus confirming the diagnosis of compound odontome (**Figure 5E**).

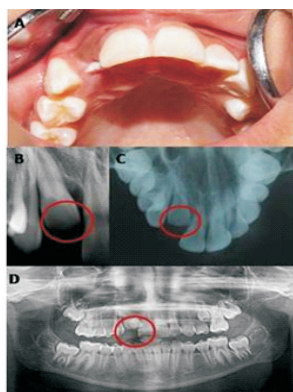


Figure 4. A. Intraoral photograph after 10 days showing spontaneous eruption of 12. B, C & D. IOPA, occlusal radiograph and OPG depicting total removal of the odontome.

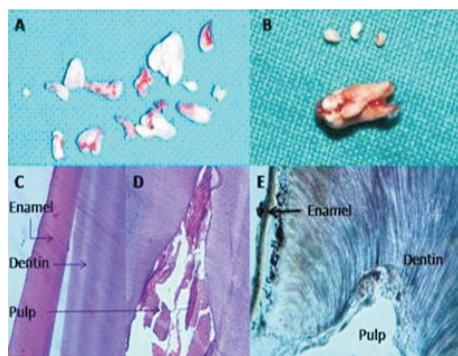


Figure 5. A. Enucleated 16-18 calcified structures of denticulo particulate compound odontome (case 1). B. Enucleated calcified masses and fused denticles (case 2). C & D. decalcified sections showing enamel, dentin and pulp in normal relationship. E. Ground section showing the dental tissues.

Discussion

The term “odontoma” was coined by Paul Broca in 1867. Odontomas are relatively common odontogenic developmental anomalies found in jaw⁽⁶⁾. According to Gyulai-Gaál et al, odontomas are benign calcifying hamartomas and are the most prevalent type of odontogenic jaw tumors among patients younger than 20 years⁽⁷⁾. A large amount of odontomas present clinically as small lesions, cause no signs or symptoms, and are usually detected during routine radiologic examination. However frequent clinical manifestations associated with odontomas are impacted permanent teeth, swelling, retained deciduous teeth, malpositioning of teeth and rarely pain and infection⁽⁶⁾.

The differentiation between compound and complex odontome is well documented^(1,3,8). A differential diagnosis is usually made by comparing the degrees of morphodifferentiation and histodifferentiation of the dental hard tissues. In comparison to visual and manual palpation, radiographic examination is the most effective clinical method to diagnose odontomas. In case of compound odontome radiographic image shows comparatively well organized malformed teeth or tooth like structures or denticles of varying size and shape surrounded by a narrow radiolucent zone. All the radiographic features in the presented cases were consistent with this description. On the other hand, complex odontome is characterized by an irregular mass of calcified material surrounded by a narrow radiolucent band with a smooth outer periphery, which usually will be located between roots of teeth⁽⁹⁾. However, a definite diagnosis can be made only by histopathological examination.

The histological examination of odontomas often shows the presence of enamel matrix, dentin, pulp tissue, and cementum that can, but need not, exhibit a normal relationship^(1,7). Compound odontomas are formed by tooth-like structures which resemble pulp tissue in the central portion surrounded by a dentin shell and partially covered by enamel. Complex odontomas are conglomerates without orientation of dentin, enamel, enamel matrix, cementum, and areas of pulp tissue. The capsule of connective tissue that surrounds an odontoma resembles the follicle that covers a normal tooth⁽²⁾. We hereby presented two case reports showing multiple calcified tooth like structures or denticles, confirming the diagnosis of compound odontomes.

According to Kaban, odontomas should be removed when the permanent teeth adjacent to the lesion exhibit about one half of their root development because this ensures safety of the normal permanent teeth and prevents interference with their eruption⁽¹⁰⁾. In both the cases, we done surgical enucleation of compound odontomes under local anaesthesia.



Conclusion

An odontoma has a restricted growth potential, but it should be removed since it contains various tooth formulations that can predispose to cystic change, delay eruption of permanent teeth, and cause considerable destruction of bone. Clinical experience suggests and the dental literature supports that an individualized radiographic examination of any pediatric patient that presents clinical evidence of delayed permanent tooth eruption or temporary tooth displacement with or without a history of previous dental trauma should be performed.

References

1. Neville BW, Damm DD, Allen CM, Bouquot JE. Oral and Maxillofacial Pathology. Philadelphia: Saunders, 1995, pp 531-533.
2. de Oliveira BH, Campos V, Marçal S. Compound odontoma-Diagnosis and treatment: Three case reports. *Pediatr Dent* 2001; 23:151-157.
3. Shafer WG, Hine MK, Levy BM. A text book of oral pathology. 4th edn. Philadelphia: W.B. Saunders Co 1983; 308-311.
4. Satish V, Prabhadevi MC, Sharma R. Odontome: A brief review. *IJCPD* sep dec 2011; 4:177-185.
5. de Tolendo OA, Bormann EP, Bezerra ACB. Odontomas - a report of 3 cases. *Bra Dent J* 1992;3:59-66.
6. de Andrade Santos PP, Barroso KMA, de Souza LB, de Costa Miguel MC, da Silveira EJD. Odontomas: Clinicopathologic study of 104 cases and a case report of compound odontoma associated in an unerupted maxillary central incisor in a child. *Inter Denti Afri Ed* 2012; 2:32-39.
7. Gyulai-Gaál S, Takács D, Szabó G, Suba Z. Mixed Odontogenic Tumors in Children and Adolescents. *J Craniofac Surg* 2007; 18:1338-1342.
8. Satish V, Sharma R, Bhat M, Rahman F, Maganur PC. Compound composite odontome (denticulo-particulate type) associated with impacted permanent lateral incisor: A case report. *Indian J Stomatol* 2012; 3:73-76.
9. White SC, Pharoah MJ. Oral radiology - Principles and Interpretation. 4th edn. Mosby 2000; 315-317.
10. Kaban LB, Troulis MJ. Dentoalveolar surgery. In: *Pediatric Oral and Maxillofacial Surgery*. Philadelphia: Saunders; 2004. p. 140.