

Aggressive Periodontitis: A Case Report with Exome Sequencing and Functional Characterization of Identified Variant

**, ** Awotoye WO, **Ayanbadejo P, ** Eliason S, ∞Umezudike K, ∞Ogundana A, **Su Dan, ∞∞∞∞Krongbaramée T, ∞∞∞∞Aladenika E, ∞∞∞∞,α Alade A, *, ∞∞∞∞Oladayo AM, β Akinshipo A, ∞∞∞∞Busch T, ψ Adeyemo WL, ** Amendt BA, *, ∞∞∞∞*Butali A*

Correspondence: Butali A,
Email: azeez-butali@uiowa.edu

**Iowa Institute for Oral Health Research, University of Iowa, Iowa City, IA, U.S.*

***Department of Orthodontics, College of Dentistry and Dental Clinics, University of Iowa, IA, U.S.*

****Department Preventive Dentistry Faculty of Dental Sciences College of Medicine, University of Lagos, ∞ Lagos, Nigeria*

*****Department of Anatomy and Cell Biology, University of Iowa, IA, U.S.*

∞Department of Preventive Dentistry, Lagos University Teaching Hospital, Lagos, Nigeria

∞∞Department of Endodontics, College of Dentistry and Dental Clinics, University of Iowa, IA, U.S.

∞∞∞Division of Endodontics, Department of Restorative Dentistry & Periodontology, Faculty of Dentistry, Chiang Mai University, Chiang Mai, Thailand

∞∞∞∞Department of Oral Pathology, Radiology and Medicine, College of Dentistry, University of Iowa, Iowa City, IA, U.S.

αDepartment of Epidemiology, College of Public Health, University of Iowa, Iowa City, IA, U.S.

βDepartment of Oral and Maxillofacial Pathology/Biology, University of Lagos, Lagos, Nigeria

ψDepartment of Oral and Maxillofacial Surgery, University of Lagos, Lagos, Nigeria

ABSTRACT

Objective: Aggressive periodontitis (AgP) is characterized by rapid and progressive destruction of the periodontal tissues and eventual tooth loss. Genetic risk contributions have been explored and rare mutations in nucleotide binding oligomerization domain containing 2 (NOD2) were reported in affected Japanese families. We therefore investigated the role of protein-altering NOD2 variants in this periodontal disease within a Nigerian cohort.

Materials and Methods: Sequencing analysis of the coding regions of NOD2 was conducted to identify the pathogenic protein-altering variants in individuals with AgP using: (1) InSilico tools and clinical variant classification system (based on American College of Medical Genetics and Genomics); (2) Immunofluorescence staining to understand the expression pattern of Nod2 in the developing tooth in Wildtype (c57 blk6) mice; and (3) In vitro cell based assay to understand the variant protein function.

Results: We discovered a novel nonsense NOD2 variant (c.835G>T; p.Glu279Ter) in one family with AgP. This truncating protein variant is clinically pathogenic, and the gene-product predictably lacks the nucleotide binding domain (NBD) and leucine-rich repeats (LRRs) domains: domains regulating inflammatory responses. Murine studies suggest that this gene contributes to tooth development. In vitro analysis suggests a dominant-negative effect of the variant. NOD2 gene is expressed in the immune cells and periodontal tissues and regulates the inflammatory response within this tissue.

Conclusion: Our study identified a novel nonsense mutation in a protein-coding gene

Key words: Genomics, Craniofacial biology/genetics, Aggressive periodontitis, Molecular genetics, Bioinformatics, Bone loss

that plays a significant role in human innate immunity. This truncating variant was found in one family and results in a dominant-negative effect, which could explain the exacerbated immune response to pathogens in the pathogenesis of this periodontal disease.

INTRODUCTION

Stage-III-or-IV-Grade-C periodontitis is a new American Academy of Periodontology (AAP 2018) classification. It was previously known as Aggressive Periodontitis (AgP), a disease that affects the supporting tissues of the teeth. It is characterized by a rapid and progressive loss of the periodontal supporting tissues of the teeth. The connective tissue and bone losses are severe, with a clinical attachment loss of more than 5mm and bone loss above 33% of the alveolar bone volume¹. The rapid progression of the disease is not directly related to the amount of plaque present in the mouth and eventually results in tooth loss if progression is not halted.

Based on the number of teeth lost, AgP was classified into localized and generalized forms. Both forms occur at an early age, with the localized form affecting the first molars and incisors while the generalized form affects other teeth in addition to the first molars and incisors. With a global prevalence of 1.6%, the prevalence of this condition varies by population with the highest prevalence of 4.2% reported in the African population². The inability to masticate effectively as a result of tooth loss has been shown to affect the oral health-related quality of life³. In addition to the exfoliation of teeth due to the alveolar bone loss, prosthetic teeth replacements are also impacted due to the loss of adequate support for these prostheses. Hence, it is important to prevent the progression of the disease to save the tooth and prevent edentulism.

Immune responses to periodontal pathogens have been implicated in the pathogenesis of this condition. The muramyl dipeptides (MDPs) present on the cell walls of gram-negative anaerobes have been reported in the etiopathogenesis of this disease. Most implicated bacteria are *Aggregatibacter actinomycetemcomitans* (Aa) and *Porphyromonas gingivalis*⁴. Despite the reports suggesting that this

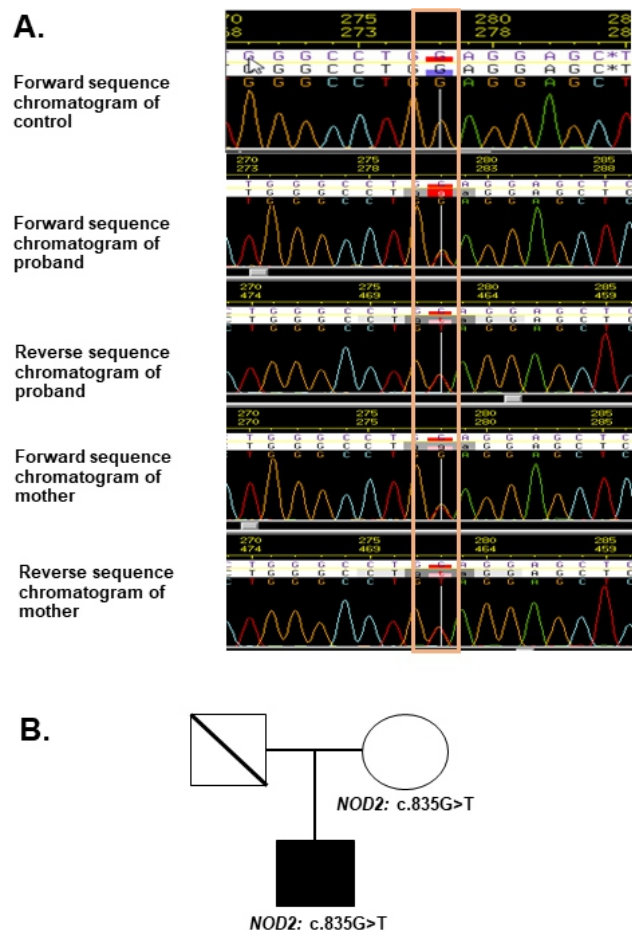
disease is genetically complex,⁵ genetic studies of this disease have not been successful in identifying specific AgP risk genes⁶. However, a whole-exome sequencing analysis identified rare variants in NOD2 that contribute to the risk of AgP in Japanese families⁷. NOD2 encodes a member of the nucleotide-binding oligomerization domain receptors (NLRs) which plays a role in innate immunity⁷.

Here, we investigated the coding region of NOD2 gene for pathogenic protein-altering variants that may explain the developmental pathogenesis of AgP in this cohort. Based on our detailed investigation, we report a novel nonsense NOD2 variant in one African family with stage-III-or-IV-grade-C periodontitis cohort.

MATERIALS AND METHODS

Participants and Samples Collection

Figure 1:



template controls respectively. Amplified DNA products were confirmed on an SDS-page gel and sent to Functional Biosciences (<http://order.functionalfbio.com/seq/index>) for sequencing. In calling the variants (SNVs and Indels), we compared the sequenced data with the human genome consensus sequence using the build GRCh38/Hg38. We ascertained the variants minor allele frequencies by searching the variant against population databases including Genome Aggregation Database (gnomAD: <https://gnomad.broadinstitute.org/>), 1000 Genomes database (<http://www.1000genomes.org/>), Exome Variant Server database (<http://snp.gs.washington.edu/EVS/>), and Exome Aggregation Consortium database (<http://exac.broadinstitute.org/>).

Identified variants were confirmed by resequencing in the forward, and reverse direction and segregation analyses were done to confirm the inheritance pattern. The functional effects due to the variants were analyzed using bioinformatics predictions tools such as Polymorphism Phenotyping (PolyPhen2); <http://genetics.bwh.harvard.edu/pph2/>⁹; Sorting Intolerant From Tolerant (SIFT; <http://sift.jcvi.org/>)¹⁰, Have Your Protein Explained (HOPE; <http://www.cmbi.ru.nl/hope>)¹¹ and Combined Annotation Dependent Depletion (CADD; <https://cadd.gs.washington.edu/>). Additionally, we used the ACMG criteria to classify the variants within the range of benign to pathogenic.

Clones / Cloning

Nod2 WT and mutant versions were cloned into pCDNA3.1 and confirmed by sequence analysis. Stable clones were generated in Chinese hamster ovary (CHO) cells by linearization/transfection and selection with G418 (200ug/ml) in CHO cells. Expression of Nod2 was analyzed by qPCR for RNA and Western blot for stable protein production (Nod2 antibody: Abcam Myc tagged antibody: Cell signaling).

Cell Growth Curves

Cells were plated at 1 x10⁵ cells/well in triplicate in 12 well plates and allowed 2 hours to attach —3 wells for each cell line were trypsinized, diluted and counted at 0,

24, 48 and 72 hours using a hemocytometer. Each bar represented 9 independent wells, with each experiment done in triplicate and repeated 3 times.

Scratch/Cell Migration Assay

Cells were plated in 6 well plates at 5x10⁶ cells and allowed to become confluent-growth for 12 hours. At this time, a yellow tip was used to make a scratch in the monolayer, and the scratch was rinsed x 2 in PBS and media was added back. Photos were taken at the time of the scratch and at 12 hours and 24 hours post scratch. Image J was used to measure the μ m distance of the scratch that remained open using the scale bar as a reference measurement.

Mouse Studies and Immunostaining

All animals were housed, and all procedures performed in accordance with the guidelines approved by the University of Iowa Office of Animal Care. All experimental procedures were approved in accordance with the University of Iowa IACUC guidelines. Our protocols complied with the ARRIVE 2.0 guidelines. For embryonic staging experiments, the observed vaginal plug date of the female was designated as E0.5. Embryos were collected at the required time point. IHF staining in normal mouse embryonic tissue. A single liter of E18.5 mouse embryos and P1 pups were fixed, embedded, and sectioned at 7 μ m. Paraffin sections were subjected to antigen retrieval and probed with the Nod2 antibody (Abcam) as previously described¹² n=3, representative image shown. The Nod2 antibody used in these assays produced a clean single band by Western blot analysis.

NFK β Luciferase Assays

Stable CHO cell lines were transfected with the NFK β reporter which was a gift from Johannes A. Schmid (Addgene plasmid # 111216; <http://n2t.net/addgene:111216>; RRID:Addgene_111216) using PEI and after 24 hours, the polyethyleneimine (PEI) was removed and replaced with DMEM media or DMEM media with 0.5 or 2 ug/ml LPS. Cells were incubated for 12 hours and then lysed and assayed for luciferase activity as previously described¹³.

qPCR Analysis

Expression of genes by qPCR was measured

A Case Report with Exome Sequencing and Functional Characterization of Identified Variant

for the stable cells lines; and with control and LPS exposure in the stable, CHO cells by Triazol extraction and RNA analysis (Fisher), cDNA synthesis (Takara biotechnology) and qPCR analysis.

We used data from our previously published periodontitis mouse model¹⁴. Briefly, 20µg Porphyromonas gingivalis lipopolysaccharide (Pg-LPS) was injected into the interdental gingiva of the mice¹⁴. This was repeated every other day for 2 weeks* before mice were sacrificed. After that RNA extraction and PCR was performed. As control, PBS was injected into the interdental gingival of the control mice¹⁴.

RESULTS

Novel Nonsense NOD2 mutation found in AgP Family

Our targeted sequencing analysis resulted in the identification of a nonsense NOD2 mutation in a family with AgP. The nucleotide substitution c.835G>T resulted in the mutation of the amino acid residue glutamate into premature stop codon (p.Glu279Ter, Table 1).

Table 1: SNV of NOD2 observed in family with AgP (Stage-III-or-IV-Grade-C periodontitis) showing the coding sequence position (HGVS_c) and amino acid position (HGVS_p) where the mutation occurred. CADD score showed mutation is among the top 0.1% deleterious mutations in the human genome.

*Chromosome Location	HGVS _c	HGVS _p	MAF	SIFT Score	PolyPhen2 Score	CADD Score	ACMG Class
16:50710746	c.835G>T	p.Glu279Ter	0	N/A	N/A	37	LP

N/A: Not available; *LP: Likely pathogenic

*Chromosome location based on the Human genome build GRCh38/Hg38

Segregation and Bioinformatics Analysis

In a bid to investigate the familial inheritance pattern of the identified NOD2: c.835G>T variant, we sequenced the coding region of the gene in the parent of the affected individual. Due to the unavailability of the paternal sample, we were only able to sequence the maternal sample. The truncation will likely affect the nucleotide binding domain (NBD) and the leucine rich repeats (LRRs) domains (Figure 1D) which may result in a gene product having only the caspase activation recruitment domain (CARD) that would potentially be encoded

in this mutant. This variant has a Combined Annotation Dependent Depletion (CADD) score of 37 which means that it is among the top 0.1% deleterious mutation in the human genome. Other in silico tools such as SIFT, Polyphen2 and PROVEAN could not be performed because this variant resulted in a nonsense codon. Using the ACMG criteria for classification of variants, the NOD2: c.835G>T identified in this study was classified as a likely pathogenic variant.

Protein Expression

We used stable expression lines made in CHO cells with NOD2 Wt and p.Glu279Ter mutation and determined if NOD2 was expressed when compared to CHO cells or pCDNA3.1 cells. Both NOD2 WT and NOD2 p.Glu279Ter lines showed over-expression of NOD2 at the RNA level (Figure 2A).

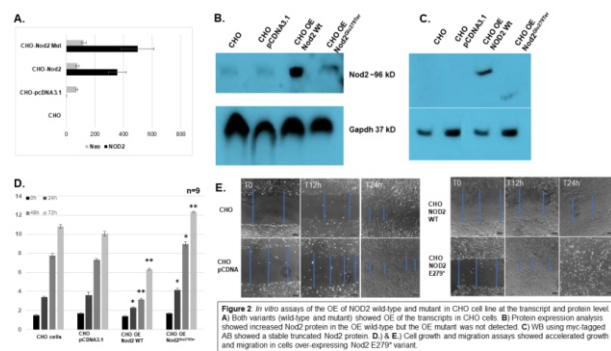


Figure 2: In vitro assays of the OE of NOD2 wild-type and mutant in CHO cell line at the transcript and protein level. A.) Both variants (wild-type and mutant) showed OE of the transcripts in CHO cells. B.) Protein expression analysis showed increased Nod2 protein in the OE wild-type but the OE mutant was not detected. C.) WB using myc-tagged AB showed a stable truncated Nod2 protein. D.) & E.) Cell growth and migration assays showed accelerated growth and migration in cells over-expressing Nod2 E279* variant.

When lysates were run out on Western blots, a single band of ~100kD was noted in CHO cells and levels increased when NOD2 Wt was overexpressed, but no additional bands could be detected in the Nod2 p. Glu279Ter OE line (Figure 2B). One explanation for this result is that the Nod2 p. Glu279Ter version does not contain the epitope for the antibody. Since pCDNA3.1 has a myc-tag at its 5' end, we used the myc-tag antibody to probe western blots. Results of the myc-Tag western show an OE Wt band of ~100kD and a band showing up in

the cells expressing the mutant allele at about ~40 kD. (Figure 2C). These results demonstrated that cells expressing the NOD2 p.Glu279Ter protein produced a stable product of the predicted size for a truncation mutation.

Further analysis of the CHO stable lines showed that cells that OE the wildtype NOD2 showed reduced growth on plates (Figure 2D) and reduced migration into a scratch in a scratch assay (Figure 2E, Supplemental Figure 1). Also, cells that OE NOD2 p.Glu279Ter mutant had accelerated growth on plates (Figure 2D) and accelerated migration into the scratch (Figure 2E, Supplemental Figure 1). The mutant version appears to have functional effects that differ from the wild-type NOD2 protein.

Mouse Nod2 Expression And Periodontitis Model

To clearly establish which cells express Nod2 in the developing mandible/tooth germ, we used normal mouse mandibular tissue sections and Nod2 expression and localization was analyzed. The incisor tooth bud was analyzed for Nod2 expression in E18.5 and P1 tissue sections. At E18.5, Nod2 expression was seen in the Odontoblast and Ameloblast layers (Figure 3).

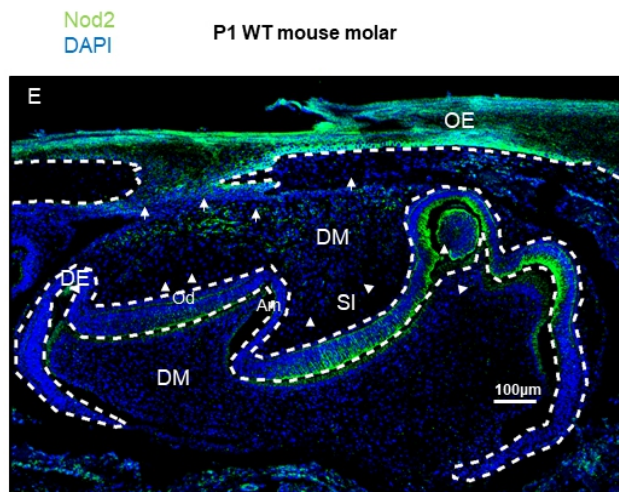
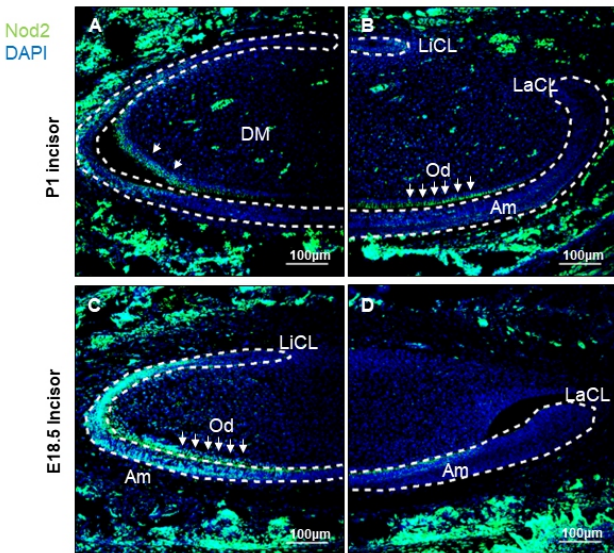


Figure 3: Paraffin slides probed by immunofluorescence using the Nod2 AB showing Nod2 expression in the P1 (A,B), E18.5 (C,D) incisor and the P1 molar (E).

*Abbreviations: LiCL – Lingual cervical loop; LaCL – Labial cervical loop; Od – Odontoblasts; Am – Ameloblasts; DM – Dental mesenchyme; DE – Dental epithelium; SI – Stratum intermedium; OE – Oral epithelium

Similar expression is seen in the P1 incisor, where ameloblasts are clearly staining positive. The P1 Molars buds showed expression in odontoblasts, Ameloblasts, the Stratum intermedium, the Stellate reticulum and in the Oral epithelium (Figure 3). Our LPS-induced periodontitis model showed that Nod2 expression was significantly increased in LPS compared to PBS control injection into gum (Figure 4A). The transcript level was assayed by quantitative polymerase chain reaction (qPCR).

NFKB and IL8 mRNA Assays

Since the nuclear factor kappaβ (NFKβ) activity has been showed to be affected by changes in NOD2 protein expression in the gut intestines and important in the development of Crohn’s disease,^{15, 16} we evaluated the effects of the OE of wild-type NOD2 or mutant NOD2 on NFKβ using a NFKβ reporter and measured for interleukin-8 (IL8) mRNA expression with or without LPS. IL8 expression has been shown to be NFKβ dependent¹⁷. Overexpression of WT NOD2 shows a reduced level of NFKβ activity (Figure 4B, Supplemental Figure 2) and a reduced expression of IL8 mRNA (Figure 4C) in response to LPS in CHO cells, as compared to CHOs or pCDNA3.1 control lines

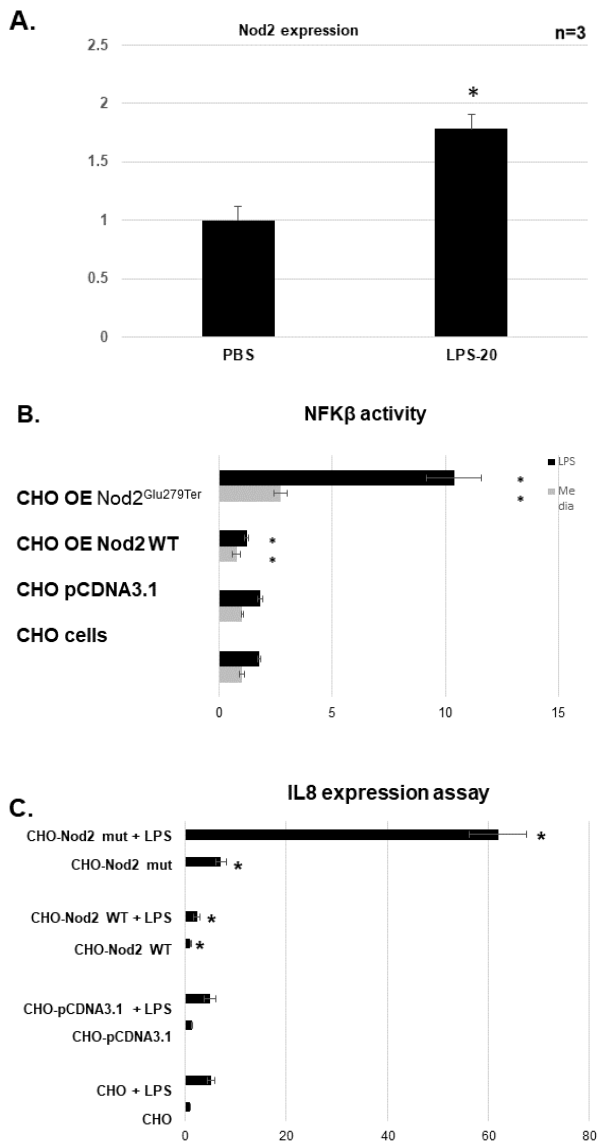


Figure 4: A.) Mouse gums injected with PBS or LPS and assayed for Nod2 expression by qPCR after 24h. Fold expression^{ΔΔCT} values. N=3, * p<0.05.

B.) Nod2 constructs and NFKB-luciferase reporter plasmids were transfected into MDPC cells with or without LPS at 2ug/ml for 24 hours. Luc units per ug were normalized to b-gal reporter for transfection efficiency and shown as fold expression over MDPC values/media only. N=3, * p<0.05

C.) CHO lines with or without 24h exposure to 2ug/ml LPS and assayed by qPCR for IL8 mRNA expression levels. N=3, * p<0.05 (Figure 4, Supplemental Figure 1). OE of Nod2 p.Glu279Ter mutant causes an increase in NFK activity (Figure 4B, Supplemental Figure 1) and IL8 mRNA levels (Figure 4C) in response to LPS in CHO cells, as compared to CHOs or pCDNA3.1 control lines (Figure 4B,C).

DISCUSSION

Through targeted sequencing analyses and in vitro functional evaluation of genetic variants, we identified a potentially pathogenic NOD2 variant (p.Glu279Ter) contributing to the risk of Stage III or IV, Grade C Periodontitis (Aggressive Periodontitis). Previously, this gene was reported to be a candidate in the developmental pathogenesis of AgP, a periodontal disease characterized by rapid and progressive destruction of the supporting tooth structures^{7, 18}. The rate of progression of the supporting tissue destruction does not correlate with the amount of potential periodontal pathogen present in the dental biofilm¹⁹. NOD2 encodes a cytosolic protein that plays an important role in innate immunity. This protein acts as an intracellular receptor that promotes the nuclear factor-kappa B activity (NF-κB), mitogen-activated protein kinases (MAPK), and caspase-1 signaling cascades. The activation of these pathways results in the expression of proinflammatory factors including CXC-chemokine ligand 8 (IL8)²⁰. This gene is expressed in the oral epithelium as well as the periodontal ligament²¹. Studies in mice showed that Nod2 role contributes to the pathogenesis of alveolar bone resorption in the mice periodontitis disease model²².

The mutation reported in this study affects an amino acid residue glutamate (p. Glu279Ter) that is highly conserved among vertebrates, thus suggesting the important role it plays in the protein function. Additionally, this mutation – a stop codon, is predicted to truncate highly conserved domains. Indeed, the truncated variant lacked the leucine-rich repeat (LRR) domain which is critical for the recognition of the muramyl dipeptide (MDP) and regulation of the immune response through inhibition of the inflammation²³. Thus, we suspect that the loss of this domain would result in an impaired immune response that is characteristic of the periodontal disease pattern observed in these patients²². Our functional analysis indicates that this gene has a role in immune response within the supporting tissues of the teeth. Expression of Nod2 in the developing tooth and supporting tooth tissues of a developing mouse suggests that this gene may also contribute to tooth development and that Nod2 expression is present in the oral cavity.

Our LPS induced periodontitis model showed a significantly increased Nod2 expression in the mouse gum tissue following LPS injection. Also, we reported differences in IL8 expression levels and NFkB reporter activity in resting cells and in response to LPS exposure in cells expressing the NOD2 variant compared to the wild-type NOD2.

Expression of IL8 results in the recruitment of neutrophils to the signaling origin. IL8 serves as a chemokine which is highly specific to neutrophils. The neutrophils have been reported to contribute to the rapid tissue destructions observable in periodontal diseases²⁴. Following the attraction of the neutrophils to the chemokine origin, these cells release enzymes on activation which destroy the connective tissues that make up the bulk of the tooth supporting structures²⁴. Our discovery of the novel nonsense NOD2 variant in a single family is a limitation of this study. Nonetheless, the novel NOD2 pathogenic variant in this study validates the discovery of the NOD2 pathogenicity in a Japanese cohort with AgP. Although we demonstrated invitro the effects of the stop-gained NOD2 variant identified in this study using CHO cells, a better cell-line would have been oral epithelial cells or cell lines derived from the periodontium. The fact that the CHO cells were derived from the ovary poses a potential sex-influenced factors in gene expression, a significant bias in the genomic research.

In summary, investigation of protein altering NOD2 variants in an African AgP cohorts resulted in the identification of a novel nonsense variant. This variant has a dominant-negative effect on the protein activity and functional analysis strongly suggests that this variant causes an increased immune response, which could result in the rapid and progressive destruction of the tooth supporting structures seen in these patients. Our findings provide additional evidence for the role of NOD2 in the developmental pathogenesis of Stage III or IV, Grade C Periodontitis (Aggressive Periodontitis). Our findings also support the translational hypothesis that modulation of the immune response to periodontal pathogens would help halt the progression of AgP in individuals carrying the genetic risk for the periodontal disease.

Primers for qPCR

.cDNA	Forward primers	Reverse primers
Btubulin	GGCCAAGGGTCACTACACG	GCAGTCGAGTTTTCACACTC
Nod2	TGGTTCAGCCTCTCAGATGA	TTCATACTGGCTGACGAAACC
IL8	ATGACTTCCAAGCTGGCCGTGGCT	TCTCAGCCCTCTTCAAAAACCTTCTC
Neomycin	CTTGCTCCTGCCGAGAAAAGT	TTCGCTTGGTGGTCAATG

REFERENCES

1. Caton JG, Armitage G, Berglundh T, et al. A new classification scheme for periodontal and peri-implant diseases and conditions - Introduction and key changes from the 1999 classification. *J Periodontol* 2018;89 Suppl1:S1-S8.
2. Bouziane A, Hamdoun R, Abouqal R, Ennibi O. Global prevalence of aggressive periodontitis: A systematic review and meta-analysis. *J Clin Periodontol* 2020;47:406-428.
3. Ustaoglu G, Goller Bulut D, Gumus K, Ankarali H. Evaluation of the effects of different forms of periodontal diseases on quality of life with OHIP-14 and SF-36 questionnaires: A cross-sectional study. *Int J Dent Hyg* 2019;17:343-349.
4. Fine DH, Kaplan JB, Kachlany SC, Schreiner HC. How we got attached to *Actinobacillus actinomycetemcomitans*: A model for infectious diseases. *Periodontol* 2000 2006;42:114-157.
5. Boughman JA, Astemborski JA, Suzuki JB. Phenotypic assessment of early onset periodontitis in sibships. *J Clin Periodontol* 1992;19:233-239.
6. Schaefer AS, Bochenek G, Manke T, et al. Validation of reported genetic risk factors for periodontitis in a large-scale replication study. *J Clin Periodontol* 2013;40:563-572.
7. Sudo T, Okada Y, Ozaki K, et al. Association of NOD2 Mutations with Aggressive Periodontitis. *J Dent Res* 2017;96:1100-1105.
8. Armitage GC. Development of a classification system for periodontal diseases and conditions. *Ann Periodontol* 1999;4:1-6.
9. Adzhubei IA, Schmidt S, Peshkin L, et al. A method and server for predicting damaging missense mutations. *Nat Methods* 2010;7:248-249.
10. Kumar P, Henikoff S, Ng PC. Predicting the effects of coding non-synonymous variants on protein function using the SIFT algorithm. *Nat Protoc* 2009;4:1073-1081.

11. Venselaar H, Te Beek TA, Kuipers RK, Hekkelman ML, Vriend G. Protein structure analysis of mutations causing inheritable diseases. An e-Science approach with life scientist friendly interfaces. *BMC Bioinformatics* 2010;11:548.
 12. Eliason S, Su D, Pinho F, et al. HMGN2 represses gene transcription via interaction with transcription factors Lef-1 and Pitx2 during amelogenesis. *J Biol Chem* 2022;298:102295.
 13. Hong L, Sharp T, Khorsand B, et al. MicroRNA-200c Represses IL-6, IL-8, and CCL-5 Expression and Enhances Osteogenic Differentiation. *PLoS One* 2016;11:e0160915.
 14. Krongbamee T, Zhu M, Qian Q, et al. Plasmid encoding microRNA-200c ameliorates periodontitis and systemic inflammation in obese mice. *Mol Ther Nucleic Acids* 2021;23:1204-1216.
 15. Maeda S, Hsu LC, Liu H, et al. Nod2 mutation in Crohn's disease potentiates NF-kappaB activity and IL-1beta processing. *Science* 2005;307:734-738.
 16. Negroni A, Pierdomenico M, Cucchiara S, Stronati L. NOD2 and inflammation: current insights. *J Inflamm Res* 2018;11:49-60.
 17. Kunsch C, Rosen CA. NF-kappa B subunit-specific regulation of the interleukin-8 promoter. *Mol Cell Biol* 1993;13:6137-6146.
 18. Mizuno N, Kume K, Nagatani Y, et al. Aggressive periodontitis and NOD2 variants. *Journal of Human Genetics* 2020;65:841-846.
 19. Abdulkareem AA, Al-Taweel FB, Al-Sharqi AJB, Gul SS, Sha A, Chapple ILC. Current concepts in the pathogenesis of periodontitis: from symbiosis to dysbiosis. *J Oral Microbiol* 2023;15:2197779.
 20. Fritz JH, Girardin SE, Fitting C, et al. Synergistic stimulation of human monocytes and dendritic cells by Toll-like receptor 4 and NOD1- and NOD2-activating agonists. *Eur J Immunol* 2005;35:2459-2470.
 21. Sugawara Y, Uehara A, Fujimoto Y, et al. Toll-like Receptors, NOD1, and NOD2 in Oral Epithelial Cells. *Journal of Dental Research* 2006;85:524-529.
 22. Prates TP, Taira TM, Holanda MC, et al. NOD2 Contributes to Porphyromonas gingivalis-induced Bone Resorption. *Journal of Dental Research* 2014;93:1155-1162.
 23. Hugot JP, Chamaillard M, Zouali H, et al. Association of NOD2 leucine-rich repeat variants with susceptibility to Crohn's disease. *Nature* 2001;411:599-603.
 24. Bickel M. The role of interleukin-8 in inflammation and mechanisms of regulation. *J Periodontol* 1993;64:456-460.
- Author contributions:** W. Awotoye, A. Butali, contributed to conception and design, data acquisition, analysis, and interpretation, drafted and critically revised the manuscript; S. Eliason, B. Amendt contributed to design, data acquisition, analysis, and interpretation, drafted and critically revised the manuscript; P. Ayanbadejo, K. Umeizudike, A. Akinshipo, W.L. Adeyemo, contributed to conception, data acquisition, analysis and interpretation, critically revised the manuscript; A. Ogundana, D. Su, T. Krongbamee, E. Aladenika, A. Alade, A. M. Oladayo, Tamara Busch, contributed to data acquisition, analysis and interpretation, critically revised the manuscript. All authors gave final approval and agreed to be accountable for all aspects of the work.
- Availability of data and materials:** The datasets used and/or analyzed during the current study are available from the corresponding author on reasonable request.
- Acknowledgments:** We are grateful to the families who voluntarily participated in this study in Nigeria. We are also grateful to all the administrative and research staff, students, nurses, and resident doctors who assisted with participants recruitment, consent, and data collection. We thank all members of the Butali and Amendt Laboratories for their helpful comments and suggestions.
- Declaration of Conflicting Interests:** The authors declared no potential conflicts of interest with respect to the research, authorship, and/or publication of this article.
- Funding:** The authors disclosed receipt of the following financial support for the research, authorship, and/or publication of this article: This research was supported by funds from the National Institutes of Health/National Institute of Dental and Craniofacial Research grants T90/R90-DE024296 to W. Awotoye, T90/R90-DE023520 to A.M. Oladayo, DE022378 and DE28300 to A. Butali; International Association for Dental Research (IADR) Smile Train Grant Award 2022 - B3299184-7B91-45DF-92C5-7820F7F11DB4 to A. Alade.