

## An Audit of the Histopathological Pattern of Ameloblastoma in Kano, Nigeria

\*Sule AA, \*\*Iyogun CA \*\*\*Adeyemi TE

\*Department of Pathology, Aminu Kano Teaching Hospital, Kano, Nigeria

\*\*Department of Oral and Maxillofacial Pathology, University of Port Harcourt, Nigeria

\*\*\*Department of Dental and Maxillofacial Surgery, Aminu Kano Teaching Hospital, Kano, Nigeria

**Correspondence: Iyogun CA**

Email: iyoguncornelius@yahoo.com

### Abstract

**Objective:** To describe the spectrum, frequency, age and sex distribution of ameloblastomas seen in Kano, as well as compare the findings with previous studies done in Nigeria, Africa and other parts of the world.

**Materials and Methods:** This was a 5 year retrospective study from 2nd January, 2010 to 31st December, 2014 of all ameloblastomas diagnosed at the pathology department of Aminu Kano Teaching Hospital, Kano, Nigeria.

**Results:** Sixty four cases of ameloblastomas were diagnosed during the five year study period with a male to female ratio of 2:1. The ages ranged from 16 to 75 years (mean age of 33.4) and relative peak age of incidence occurred in the 40 - 49 years group. Solid/Multicystic type accounted for majority (57 cases, 89.1%) of ameloblastomas followed by unicystic variant (5 cases, 7.8%), while the desmoplastic and peripheral variants comprising the remaining 2 cases (3.1%). The mandible was the commonest site of involvement accounting for 57 cases (89.1%), while maxilla and alveolar mucosa accounted for 6 cases (9.4%) and 1 case (1.6%) respectively.

**Conclusion:** This study showed that ameloblastoma has significant male predilection and affecting predominantly patients in the third to fifth decades. It revealed a higher incidence of solid/multicystic ameloblastomas over unicystic variants. The demographic and histological features are similar to reports from other parts of Nigeria and elsewhere.

**Key words:** Ameloblastomas, solid/multicystic, unicystic, desmoplastic and peripheral variants.

### Introduction

Ameloblastoma is a benign neoplasm of odontogenic epithelial origin.<sup>1</sup> Ameloblastoma constitutes 1 to 2% of tumours and cysts of the jaws.<sup>2</sup> It is the most commonly encountered odontogenic tumour in Nigeria and other developing world, but the second in most developed parts of the world.<sup>3-6</sup>

Ameloblastoma may arise from epithelial lining of a dentigerous cyst, from the remnants of the dental lamina and enamel organ or from the basal layer of the oral mucosa, sometimes in a multicentric fashion.<sup>7-11</sup> Ameloblastoma appears most commonly in the third to fifth decades, but it has also been described in children.<sup>12,13</sup> Over 80% occur in the mandible, with 70% of this arising in the molar-ramus

area. They are usually asymptomatic and present as a slow growing but locally persistent facial swelling or as an incidental radiographic finding. Despite being a benign neoplasm, it is locally destructive and has a high rate of recurrence if not completely removed. Clinical duration may range from a few weeks to 50 years.<sup>2,14,15,16</sup>

According to the classification of odontogenic tumours by World Health Organization (WHO) in 2005, ameloblastoma is classified into solid/multicystic, extraosseous/peripheral, desmoplastic and unicystic types.<sup>1</sup> The solid/multicystic type is further subdivided into two basic histopathologic patterns, the follicular and plexiform. The follicular type can further be subdivided into acanthomatous, basal cell,

granular cell and spindle cell variants, it consists of islands of odontogenic epithelium within a fibrous stroma, while the plexiform pattern contains basal cells arranged in anastomosing strands with an inconspicuous stellate reticulum with delicate stroma, often with cyst-like degeneration. The extra-osseous/peripheral type has the same histopathological cell types and patterns as solid/multicystic type. The desmoplastic type demonstrates epithelial tumour islands with very irregular shape and a pointed, stellate appearance. The unicystic type is divided into mural and luminal variants. In mural unicystic ameloblastoma, there are invasive islands of ameloblastomatous epithelium in connective tissue wall not involving the entire epithelium while in luminal type, the tumour cells are confined to the luminal surface.<sup>17</sup>

There has not been any published work on ameloblastoma from our centre, which is a major referral centre for histopathological services in Northern Nigeria. The aim of this study is to document the histopathologic spectrum of ameloblastomas, their age, sex and anatomical site distribution as seen in the histopathology department of Aminu Kano Teaching Hospital, Kano and to compare our findings with those from previous series.

### Materials and Methods

This was a 5 year retrospective study of all histologically diagnosed ameloblastomas at the pathology department of Aminu Kano Teaching

Hospital, Kano, Nigeria from 2nd January, 2010 to 31st December, 2014. All biopsies were fixed in 10% formal saline, routinely processed for paraffin embedding then microtome sectioned at 5µm and the resulting slides stained with Haematoxylin and Eosin. The corresponding slides were retrieved from the archive and reviewed by the study. Authors and any inter-observer variation were resolved before collation of results and the tumours classified according to WHO histological classification of ameloblastomas.<sup>1</sup> The data were subsequently analysed using SPSS version 20 and presented as frequency tables.

### Results

A total of 64 cases of ameloblastomas was seen during the 5 year study period. 57 (89.1%) were diagnosed as solid/multicystic, 5(7.8%) unicystic, 1 (1.6%) desmoplastic and 1(1.6%) peripheral. Forty three (67.2%) were males while 21 (32.8%) were females giving a male to female ratio of 2:1. There was no statistical significant difference between the gender and histological subtypes ( $p = 0.775$ ).

The overall age range of patients with ameloblastomas in this study was 16 – 75 years with mean age of 33.4 years and peak incidence was seen in the fourth and fifth decades. No statistical significant difference between the age and histologic subtypes ( $p = 0.611$ ) Table 1 shows relative frequency, gender and age distribution of ameloblastomas in Kano, Nigeria. (Table 1)

**Table 1: Relative frequency, gender and age distribution of ameloblastomas in Kano, Nigeria**

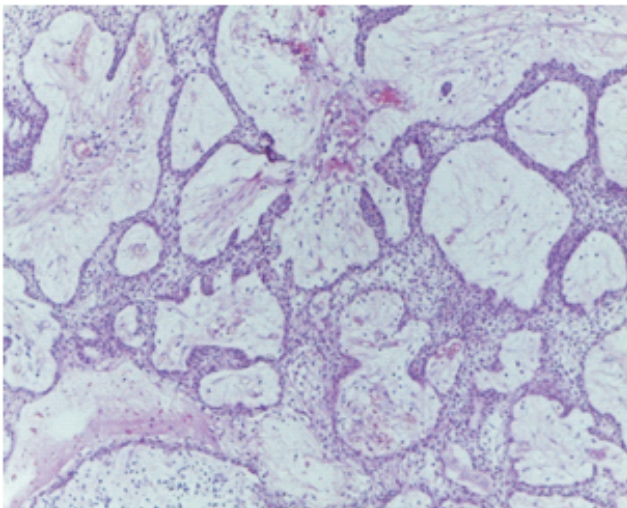
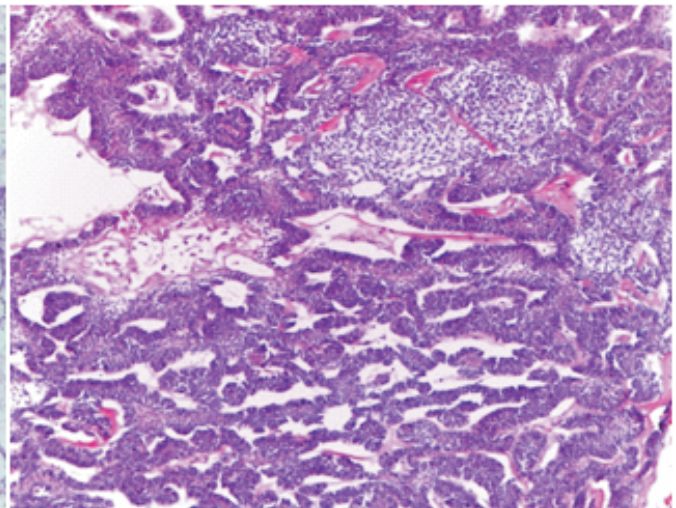
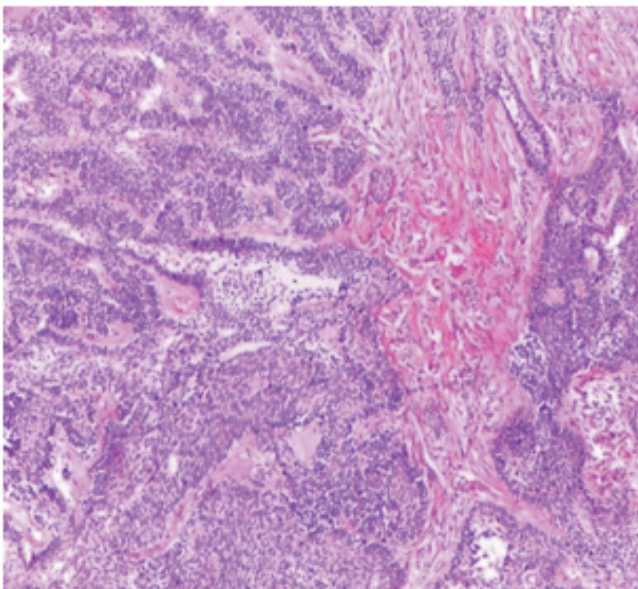
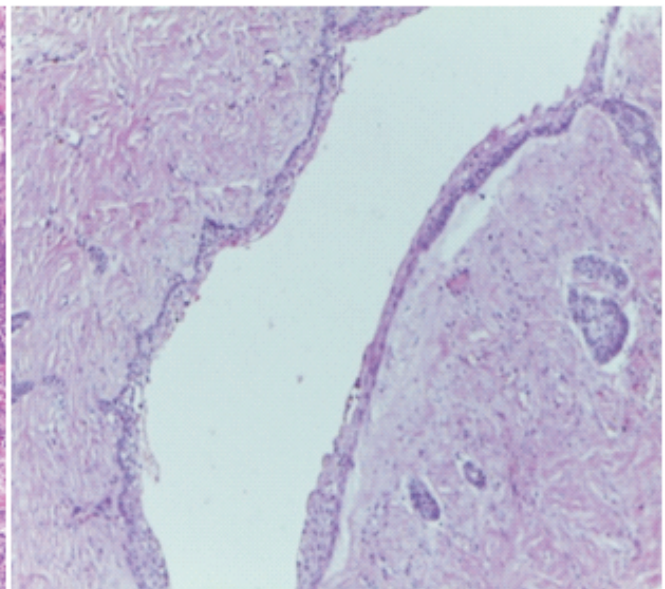
Histopathologic type	No of cases	M	F	<20 years	20 - 29 years	30 - 39 years	40 - 49 years	50 - 59 years	60 - 69 years	≥ 70 years
Solid/multicystic Follicular	28	18	10	5	7	5	7	1	1	2
Plexiform	16	11	5	1	2	4	7	2	-	-
Acanthomatous	2	2	-	-	-	1	1	-	-	-
Basal cell	1	1	-	-	-	1	-	-	-	-
Granular	1	1	-	-	-	1	-	-	-	-
Mixed	9	6	3	-	3	2	4	-	-	-
Unicystic Mural	4	2	2	-	4	-	-	-	-	-
Luminal	1	1	-	-	-	1	-	-	-	-
Peripheral	1	-	1	-	-	-	-	1	-	-
Desmoplastic	1	1	-	-	-	1	-	-	-	-
<b>Total</b>	<b>64</b>	<b>43</b>	<b>21</b>	<b>6</b>	<b>16</b>	<b>16</b>	<b>19</b>	<b>4</b>	<b>1</b>	<b>2</b>

The tumours were commonly located on the posterior mandible (75%), followed by anterior mandible (14.1%). Posterior maxilla had (9.4%), in contrast to none from anterior maxilla. Table 2 shows anatomical distribution of the ameloblastoma subtypes in Kano, Nigeria. The histological analysis shows that 57 solid/multicystic ameloblastomas comprised: follicular 28 cases (43.8%), plexiform 16 cases (25%), acanthomatous 2 cases (3.1%), basal

cell 1 case (1.6%), granular 1 case (1.6%). The 5 unicystic ameloblastomas were composed of mural 4 cases (6.3%) and one case (1.6%) of luminal. The desmoplastic and peripheral had one case each. The solid/multicystic affected 39 (61%) males and 18 (28%) females while the unicystic affected 3(4.7%) males and 2(3.1%) females (Tables 1 and 2). Figures 1 to 4 depict the histopathologic variants.

**Table 2: Anatomical distribution of the ameloblastoma subtypes in Kano, Nigeria**

Histopathologic type	Posterior Mandible	Anterior Mandible	Posterior Maxilla	Anterior Maxilla	Alveolar Mucosa
Solid/multicystic	43	8	6	-	-
Unicystic	5	-	-	-	-
Desmoplastic	-	1	-	-	-
Peripheral	-	-	-	-	1
<b>Total</b>	<b>48</b>	<b>9</b>	<b>6</b>	<b>-</b>	<b>1</b>


**Figure 1: Follicular pattern showing epithelial islands within a loose fibrous stroma**

**Figure 2: Plexiform pattern showing anastomosing strands and cords of tumour cells**

**Figure 3: Acanthomatous pattern showing squamous metaplasia within the tumour**

**Figure 4: Unicystic pattern showing lesion lined by ameloblastomatous epithelium**

## Discussion

There were 64 cases of ameloblastomas of the jaws during the 5-year study period which represents an annual hospital-based frequency of 12.8 cases per year. This number is small for the only department providing pathology services in Kano and a major referral centre for the neighbouring states.

Many reasons can be adduced for the small sample size of this study: (i) ameloblastoma is a painless lesion, slow growing and may not present early or at all, (ii) low awareness of availability of modern methods of management and (iii) low diagnostic skill in private dental outfits. This may be due to the newness of oral and maxillofacial surgical practice in Kano and also that prior to the establishment of Aminu Kano Teaching Hospital, Kano major oral and maxillofacial surgical cases were often referred to Ahmadu Bello University Teaching Hospital in neighbouring Kaduna State.

The overwhelming majority of ameloblastomas in this study was solid/multicystic (89.1%), which is consistent with other published reports<sup>12,19,20</sup>. In a study by Andressa-Incerte et al in Brazil, solid/multicystic and unicystic comprised 51-94% and 1-41% of all ameloblastomas respectively<sup>21</sup>. Our results are not in agreement with the study of Chawla et al in India which showed unicystic ameloblastoma as the most frequently encountered histological subtype (34%)<sup>22</sup>. Ledesma-Montes et al reported that 63% of their ameloblastomas derived from Mexican and Guanttemalan populations were unicystic<sup>23</sup>.

In our series, there was gender predilection with male to female ratio of 2:1. This finding contrasts most reports where ameloblastomas affect males and females equally<sup>20,22,24-30</sup>. However, our finding was comparable to the finding of Olaitan et al in Kaduna with a male to female ratio of 1.6:1<sup>18</sup>.

The youngest patient was 15 years old, while the oldest was 75 years of age. This conforms with reports across the globe<sup>20,23-26,31,32</sup>. Similarly, the mean age of 33.4 years in this study agrees with other reports in Nigeria and elsewhere.<sup>33,34</sup> The peak incidence within the fourth and fifth decades of life is also consistent with studies from other parts of the world.<sup>24-27,30,31</sup>

Ameloblastomas in this series showed striking predilection for mandible (89.1%), followed by the maxilla (9.4%) and alveolar mucosa (1.5%). This preponderance of occurrence in the mandible is in accord with other studies.<sup>20,24,25,27-31,34,35</sup>

## Conclusion

In conclusion, ameloblastomas in this study showed male predilection and predominantly affects patients

in their third to fifth decades. Solid ameloblastomas represented the majority and the mandible was the preferred site with a marked preponderance for the posterior region. The most common histological subtype was follicular variant. While a general pattern can not be drawn for Nigeria, our findings are generally consistent with global pattern in terms of histologic types, frequency, site and age distribution. There is a significant need to refine our understanding of the molecular basis of the disease to aid effective treatment outcome.

## References

1. Barnes L, Everton JW, Reichart P, Sidransky D. World Health Organization classification of tumours: Head and neck tumours. Lyon, France, IARC Press, 2005; 284-302.
2. Small LA, Waldron CA. Ameloblastoma of the jaws. *Oral Surg Oral Med Oral Pathol* 1955; 8: 281-97.
3. Arotiba JT, Ogunbiyi JO, Obiechina AE. Odontogenic tumours: A 15-year review from Ibadan, Nigeria. *Br J Oral Maxillofac Surg* 1997; 35(5):363-367.
4. Ladeinde AL, Ajayi OL, Ogunlewe MO, Adeyemo WL, Arotiba JT, Bamgbose BO. Odontogenic tumours: A review of 319 cases in a Nigerian teaching hospital. *Oral Surg Oral Med Oral Pathol Oral Radiol Endod* 2005; 99(2):191-195.
5. Regezi JA, Kerr DA, Courtney RM. Odontogenic tumours: Analysis of 706 cases. *J Oral Surg* 1978; 36(10):771-778.
6. Ochsenius G, Ortega A, Godoy L, Penafiel C, Escobar E. Odontogenic tumours in Chile. A study of 362 cases. *J Oral Pathol Med* 2002; 31(7):415-420.
7. Gardner DG. Peripheral ameloblastoma. A study of 21 cases, including 5 reported as basal cell carcinoma of gingiva. *Cancer* 1977; 39:1625-1633.
8. Gorlin RJ. Odontogenic tumours. In Gorlin RJ, Goldman HM: *Thoma's oral pathology*, 6 ed. Sr louis, 1970, Mosby.
9. Richardson JF, Greer RO. Ameloblastoma of mucosal origin. *Arch Otolaryngol* 1974; 100:174-175.
10. Vickers RA, Gorlin RJ. Ameloblastoma. Delineation of early histopathologic features of neoplasia. *Cancer* 1970; 26:699-710
11. Wesley RK, Borninski ER, Mintz S. Peripheral ameloblastoma. Report of a case and review of the literature. *J Oral Surg* 1977; 35:670-672.

12. Daramola JO, Ajaglae HA, Oluwasanmi JO. Ameloblastoma of the jaw in Nigerian children. A review of 16 cases. *Oral Surg Oral Med Oral Pathol* 1975;40:458-463.
13. Sehdev MK, Huvos AG, Strong EW, Gerold FP, Willis GW. Ameloblastoma of maxilla and mandible. *Cancer* 1974; 33:324-333.
14. Hoffman PJ, Baden E, Rankow RM, Potter GD. Fate of uncontrolled ameloblastoma *Oral Surg Oral Med Oral Pathol* 1968; 26:419-426.
15. Mehlich DR, Darlin DC, Masson JK. Ameloblastoma. A clinicopathologic report. *J Oral Surg* 1972; 30:9-22
16. Hong J et al. Long-term follow up on recurrence of 305 ameloblastoma cases. *Int J Oral Maxillofac Surg* 2007; 36(4):283-288
17. Philipsen HP, Reichart PA, Unicystic ameloblastoma. *Odontogenic tumours and allied lesions*; London: Quintessence Pub; 2004. pp 77-86
18. Olaitan AA, Adeola DS, Adekeye EO. Ameloblastoma. Clinical features and management of 315 cases in Kaduna, Nigeria. *J Craniomaxillofac Surg* 1993;21:351-355.
19. Arotiba GT, Ladeinde AL, Arotiba JT, Ajike SO, Ugboko VI, Ajayi OF. Ameloblastoma in Nigeria children and adolescents. A review of 79 cases. *J Oral Maxillofac Surg* 2005; 63:747-751.
20. Adebisi KE, Ugboko VI, Omoniyi-Esan GO, Ndukwe KC, Oginni FO. Clinicopathological analysis of histological variants of ameloblastoma in a suburban Nigeria population. *Head & Face Medicine* 2006; 2:42.
21. Andressa-Incerta F, Terasa-Cristnia-Ribeiro BS, Fabio-Remoa P. Ameloblastoma. Clinicopathological features from 70 cases diagnosed in a single oral pathology services in an 8-year period. *Med Oral Pathol Oral Cir Bucal* 2014;6:556-561.
22. Chawla R, Ramalingam K, Sarka A, Muddiah S. Ninety-one cases of ameloblastoma in an Indian population: A comprehensive review. *J Nat Sci Biol Med* 2013;4:310-315.
23. Ledesma-Montes C, Mosqueda-Taylor A, Carlos-Bregni R, Remero de Leon E, Palma-Guzman JM, Paez-Valencia C, et al. Ameloblastomas: A regional Latin-American multicentric study. *Oral Dis* 2007;13:303-307
24. Fulco GM, Nonaka CFW, Souza LB, Miguel MCC, Pinto LR. Solid ameloblastomas-retrospective, clinical and histopathologic study of 54 cases. *Braz J Otorhinolaryngol* 2010; 76:176-177.
25. Darshani GKS, Jayasooriya PR, Rambukewela IK, Tilakaratne WM. A clinico-pathological comparison between mandibular and maxillary ameloblastomas in Sri Lanka. *J Oral Pathol Med* 2010; 39:236-241.
26. Dhanuthai K, et al. Ameloblastoma. A multicentric study. *Oral Surg Oral Med Oral Pathol Oral Radiol* 2012;113:782-788.
27. Kim SG, Jang HS. Ameloblastoma. A clinical, radiographic, and histopathologic analysis of 71 cases. *Oral Surg Oral Med Oral Pathol Oral Radiol Endod* 2001; 91:649-653.
28. Siar CH, Lau SH, Ng KH. Ameloblastomas of the jaws: a retrospective analysis of 340 cases in a Malaysian population. *J Oral Maxillofac Surg* 2012; 70:608-615.
29. Dias CD, Brandao TB, Soares FA, Lourenco SV. Ameloblastomas: clinical-histopathological evaluation of 85 cases with emphasis on squamous metaplasia and keratinization aspect. *Acta Odontol Scand* 2013; 71:1651-1655.
30. Martins RH, Sobrinho JA, Rapoport A, Rosa MP. Histopathologic features and management of ameloblastoma: Study of 20 cases. *Sao Paulo Med J* 1999; 117:174.
31. Fregmani ER, de Cruz Perez DE, de Almeida OP, Kowalski LP, Soares FA, de Abreu Alves FA. Clinicopathological study and treatment outcomes of 121 cases of ameloblastomas. *Int J Craniomaxillofac Surg* 2010; 39:145-149.
32. Hertog D, Bloememna E, Aartman IHA, Van der Waal I. Histopathology of ameloblastoma of the jaws; some critical observation based on a 40 year single institution experience. *Med Oral Pathol Oral Cir Bucal* 2012; 17:76-82.
33. Bassey GO, Osunde OD, Anyanечи CE. Maxillofacial tumours and tumour-like lesions in a Nigerian Teaching Hospital: An eleven year retrospective analysis. *Afri Health Sci* 2014;14(1):56-63.
34. Waldron CD, El-Mofty SK. A histopathologic study of 116 ameloblastoma with special reference to the desmoplastic variant. *Oral Surg Oral Med Oral Pathol* 1987; 63:441-451.
35. Adeline VL, Dimba EAO, Wakoli KA, Nijru AK, Awange DO, Onyango JF, et al. Clinicopathologic features of ameloblastoma in Kenya. A 10 year audit. *J Craniofac Surg* 2008; 19:1589-1593.