

## Primary intraosseous mucoepidermoid carcinoma of maxilla- case report

\*Kumar A, Shetty DC, Rai CH, Kumar K

\*Department of Oral Maxillofacial Pathology and Microbiology, I.T.S. Center for Dental Studies and Research, uradnagar, Ghaziabad India

\*Correspondence: Kumar A

Email: drbansal77ynr@yahoo.co.in

### Abstract

Primary intraosseous mucoepidermoid carcinoma (PIOC) of the jaw bones is an extremely rare malignant salivary gland tumour constituting 2-4.3% of all the reported mucoepidermoid carcinomas (MEC). It is commonly seen in the posterior part of the mandible and rare in maxilla. The aetiopathogenesis of the PIOC is not completely understood. We hereby, report a case of PIOC of the maxilla in an 18 year old male patient. An incisional biopsy was performed, and the histopathological findings confirmed intermediate-grade mucoepidermoid carcinoma. Maxillary MEC have a worse prognosis than mandibular cases and it should be followed-up for a longer period due to the possibility of late recurrence or regional metastasis.

**Keywords:** Intraosseous, maxilla, mucoepidermoid carcinoma.

### Introduction

Mucoepidermoid Carcinoma (MEC) is the most commonly occurring malignant salivary gland neoplasm comprising 2.8%-15% of all salivary gland tumours<sup>(1)</sup>. It was first described by Masson and Berger in 1924<sup>(2)</sup>. Eversole reviewed 815 cases and found that of the major salivary gland tumours, 89.6% involved the parotid, 8.4% submandibular and 0.4% sublingual gland. The palate was the most common site for minor salivary gland involvement, accounting for 41.1% of intraoral lesions<sup>(3)</sup>. In 1945, Stewart et al described its mucus secreting and epidermal cellular elements thus establishing it as distinct pathologic entity<sup>(4)</sup>. Histopathologically, this tumor is classified as of either a high grade or a low grade, depending upon the ratio of epidermal cells to mucous cells<sup>(5)</sup>. Lepp in 1939 first reported an intraosseous mucoepidermoid carcinoma of mandible<sup>(6)</sup>, and Bhaskar in 1963 reported two cases and analyzed the criteria for their central origin, histology and pathogenesis<sup>(7)</sup>. Rarely, it may occur intraosseously from the epithelial lining of the odontogenic cyst and/or epithelial remnants of ectopic salivary glands. Aberrant salivary gland neoplasms arising within jaws as primary central bony lesions are extremely rare, comprising 2%-4.3% of all MECs reported<sup>(8,9)</sup>. Central MEC is a rare but well-known entity affecting the jaw bones<sup>(3,8)</sup>. The incidence rate is 2 to 3 times less in maxilla than mandible<sup>(10)</sup>. Its pathogenesis, radiological and histopathological aspects have been extensively discussed<sup>(8,10)</sup>. In 1991, after a systematic review of its histology and degree of differentiation the WHO recommended that the term "mucoepidermoid tumour" to be changed to "mucoepidermoid carcinoma"<sup>(11)</sup>. We hereby report a case of a primary central MEC present in the maxilla of an 18-year-old male.

### Case report

An 18 year old male patient reported to the Out Patient Department (OPD) of I.T.S- Centre for Dental Studies and Research (CDSR) with the chief complaint of painful swelling in the posterior region of the left side of the maxilla since 2 years which gradually increased to the present size. Swelling was oval in shape, firm, intact normal coloured overlying skin with smooth margins present in relation to 25 to 28 region.

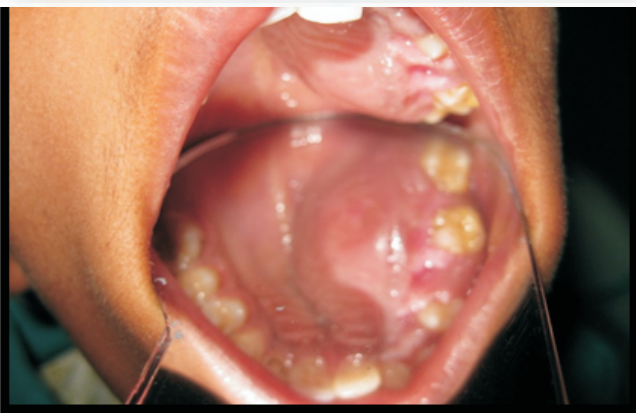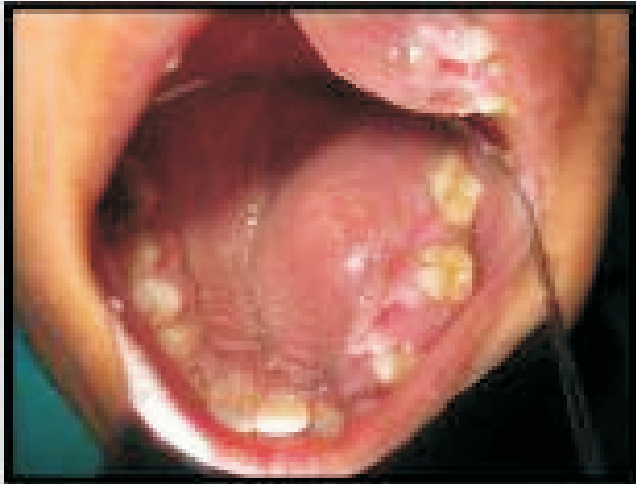No history of cigarette smoking, alcoholism or "betel quid" chewing. No significant medical or family history was noted. Cervical lymphadenopathy was absent. General physical examination revealed that the patient was moderately built and nourished. All the vital signs were within normal limits.

Intra oral examination revealed a smooth surface, pale pink, firm dome shaped swelling with intact overlying On roentgenographic examination the panoramic view showed multilocular radiolucency with radiopacity and irregular margins which extends from 25 to 28 in the left side of the maxilla. (Figure 2) mucosa present on palatal side which extends from 25 to 28 region in the left side of the maxilla.

CT scan revealed a well defined multilocular radiolucent lesion which was 2.5×2.8×3.1 cm in size extending from the region of 25, 26, 27, 28 in the left posterior region of the left side of the maxilla and protruded into the adjoining maxillary sinus, elevating its floor and Osteolysis at antero lateral margin of lesion was noted. (Figure 3).

Evaluating the clinical and radiographic findings, the provisional diagnosis of an ameloblastoma was considered. We also included the differential diagnosis of odontogenic keratocyst, radicular cyst, dentigerous cyst, odontogenic myxoma and lesions of the minor salivary glands. Subsequently, an excisional biopsy was performed and cystic lining extending upto antral wall was excised.

Gross examination revealed soft tissue bits which was blackish in colour with well defined margins measuring about 1.6×2 cm, 2.4×2 cm, 0.5×0.4 cm and 0.4×0.5 cm. (Figure 4)



Figures 1(a) and 1(b). Intra oral photograph showing a dome shaped swelling on palatal side extending from 25 to 28 region

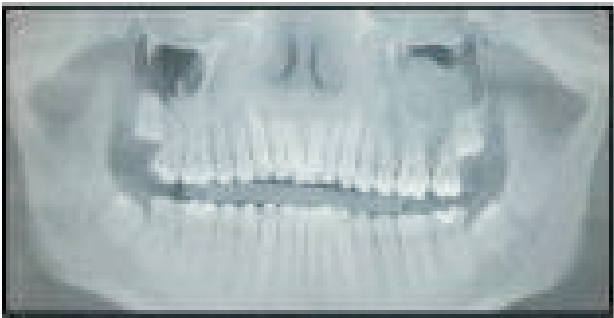

Figure 2. Panoramic view.

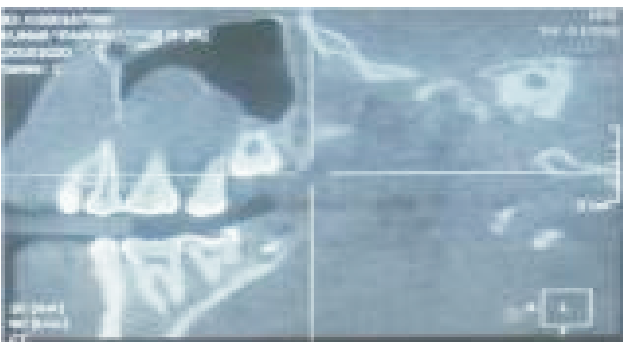
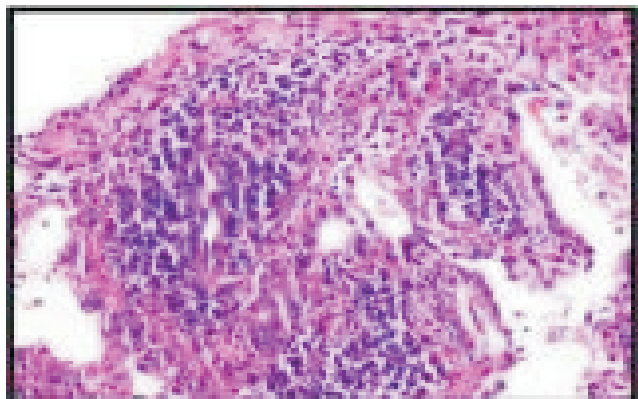
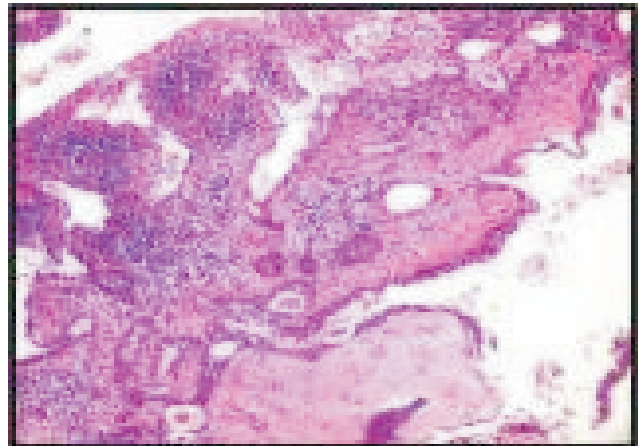


Figure 3. CT scan showing well defined unilocular expansile radiolucent lesion in the posterior region of the left side maxilla protruding into adjoining maxillary sinus.

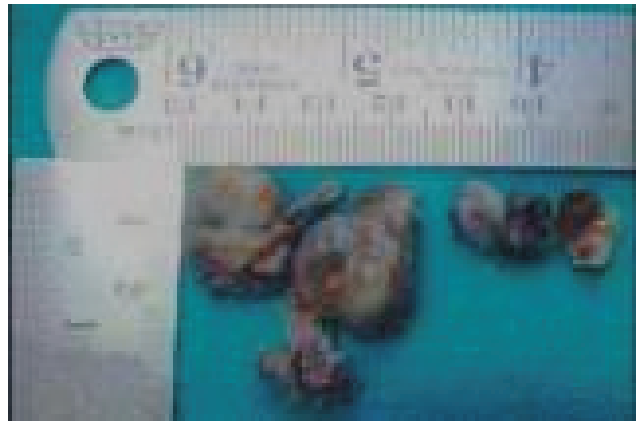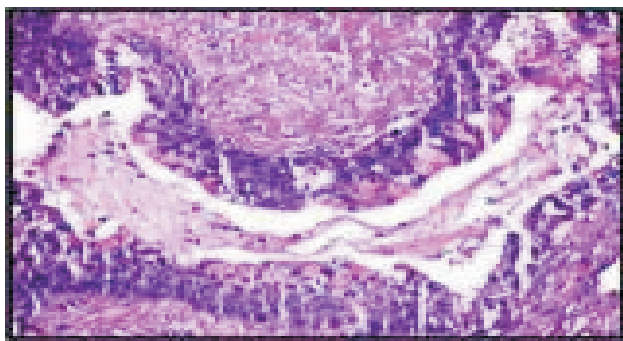
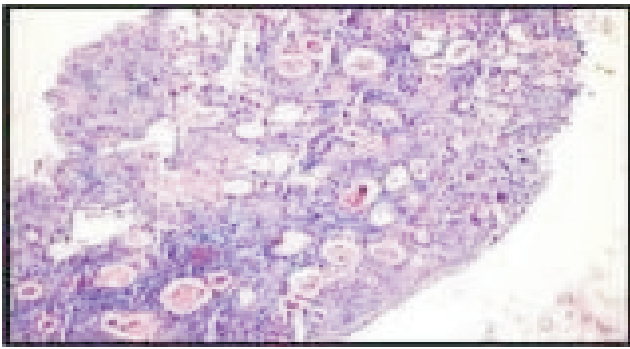


Figure 4. Gross photographs of soft tissue bits.

Histopathologic examination showed 2 to several layers thick of epithelial lining consisting of cuboidal to short columnar cells which is showing excessive proliferation into underlying stroma at places with mucous and goblet cells. (Figure 5) Islands consisting of epidermoid and mucus cells having eosinophilic material in cystic spaces are seen in connective tissue stroma which are positive for PAS and mucicarmin. (Figure 6, 7) Connective tissue stroma varies from loose edematous to hyalinized fibrous in nature. These epithelial islands are showing cellular pleomorphism and nuclear hyperchromatism along with prominent intercellular junction. These findings suggested us towards the diagnosis of intermediate grade of MEC.



Figures 5(a) and 5(b). H& E stained photomicrograph showing cystic spaces, epidermoid cells, mucous cells.



**Figure 6 and 7. Mucicarmine and PAS stained photomicrograph (10X) showing goblet cells and mucicarmine positive material in cystic spaces.**

## Discussion

Intraosseous carcinoma arising in the jaw bones was described as a central epidermoid carcinoma by Loos in 1913<sup>(12)</sup>. Later, Pindborg coined the term "primary intraosseous carcinoma" (PIOC) in the first edition of the World Health Organization classification for the histopathological typing of the odontogenic tumours<sup>(13)</sup>. Waldron and Mustoe suggested that intraosseous mucoepidermoid carcinoma be included in primary intraosseous carcinoma of jaw as type 4<sup>(14)</sup>.

Table 1: Classification of Primary Intraosseous Carcinoma

Type 1: PIOC ex odontogenic cyst

Type 2A: Malignant ameloblastoma

Type 2B: Ameloblastic carcinoma arising de novo, exameloblastoma or exodontogenic cyst

Type 3: PIOC arising de novo

a) Keratinising type

b) Nonkeratinising type

Type 4: Intraosseous mucoepidermoid carcinoma.

Central MEC commonly occurs in fourth to fifth decade of life with more female predilection and twice occurrence in maxillae than mandible<sup>(10,15)</sup>. In this case, lesion was present in relation to the posterior maxillae in an 18 year old male patient. So, occurrence of central MEC in the maxilla of young individual cannot be overlooked. F Pires et al (2003), reviewed 173 cases of MEC and reported that among 173 cases, only 7 cases were originating from the maxillary sinus and no case was found in maxilla<sup>(10)</sup>.

The pathogenesis of the central MEC has been discussed extensively and various possible origins have been considered, including: entrapment of the retromolar mucous glands within the mandible (which later undergo

neoplastic transformation), embryonic remnants of the submandibular and sublingual glands trapped within the mandible during development, neoplastic transformation and invasion from the lining of the maxillary sinus, neoplastic transformation of the mucus-secreting cells from the epithelial lining of the dentigerous cyst associated with impacted third molars<sup>(16,17)</sup>.

The possibilities of the origin of the central MEC in this report may be: neoplastic transformation of entrapped minor salivary glands within the maxilla, neoplastic transformation and invasion from the lining of the maxillary sinus. Maxillary MEC have a worse prognosis than mandibular cases<sup>(10)</sup>.

The criteria for diagnosing CMCs include: (a) presence of a radiographic distinct osteolytic lesion (b) positive mucicarmine staining (c) absence of rupture of one or more cortical plates (d) clinical and histological exclusion of a metastasis or an odontogenic lesion (e) exclusion of the origin from a soft tissue salivary gland (f) histologic confirmation<sup>(18)</sup>.

Our case showed positive staining for PAS and mucicarmine which confirms presence of mucin. Both buccal and lingual cortices were intact and histologically it was confirmed as intermediate MEC as the intermediate cells are predominant than mucous and epidermoid cells. Moreover we excluded other possibilities as metastases and odontogenic lesions. These findings showed that our diagnosis of intermediate MEC justifies the published criteria of diagnosing MEC.

Brookstone and Huvos had put forward a staging system based on condition of the overlying bone. Lesions with intact cortical plates with no evidence of bony expansion offer the best prognosis and indicate stage I disease. Stage II disease is surrounded by intact cortical bone that has undergone some degree of expansion. Any instance of cortical perforation, breakdown of the overlying periosteum or nodal spread is best categorized clinically as stage III disease<sup>(18)</sup>. The case presented here showed intact buccal and lingual cortices with no cortical expansion and could be imputed as stage I disease. This grading system seems to be useful, adjunctive to clinical stage, localization and histological grade of the tumours, in establishing proper management and prognosis of central MEC.

In conclusion, central MEC in the jaws is a rare entity. The posterior part of the mandible is the common site. However, occurrence in the maxilla cannot be overlooked. The usual fallacies with regard to histopathological reporting are the abject refusal on the part of the pathologist in the possibilities of rare tumour occurring in the unknown sites. Thus, a diligent search for the rare neoplasms or common neoplasms in rare sites needs to be remembered when confirming a diagnosis. Use of CT scan greatly helps in the diagnosis as well as to identify involvement of adjacent vital structures, which may change the treatment as well as the prognosis. Central MEC cases should be followed-up for a longer period due to the possibility of late recurrence or regional metastasis. However, death may occur as a result of extension into vital structures such as the base of the brain<sup>(15)</sup>. As a rule, even being low-grade tumours, CMC should be managed by wide local resection<sup>(19)</sup>.



## References

1. Brandwein MS, Ivanov K, Wallace DI, Hille JJ, Wang B, Fahmy A, Bodian C, Urken ML, Gnepp DR, Huvos A, Lumerman H, Mills SE. Mucoepidermoid carcinoma: a clinicopathological study of 80 patients with special reference to histological grading. *Am J Surg Pathol* 2001;25:835-845.
2. Sumanth KN, Mainali A, Ongole R, Pai MR. Mucoepidermoid carcinoma: "A Mimicker"? *Nepal Dent Assoc* 2009;10:31-34.
3. Eversole LR Mucoepidermoid Carcinoma: Review of 815 reported cases. *Oral Surg Oral Med Oral Pathol* 1970;28:490-495.
4. Stewart FW, Foote FW, Becker WF. Mucoepidermoid tumors of salivary glands. *Ann Surg* 1945;122:820.
5. Greenberg MS, Glick M. *Burket's Oral Medicine Diagnosis and Treatment*. 10th ed. Elsevier: New Delhi;2003,p235-265.
6. Lepp H Zur Kenntnis des papillar wachsenden schleimigen cystadenokarzinoms der mundhohle. *Zieglers Beitrage Z Pathol Anat* 1939;102:164-166
7. Bhaskar SN Central mucoepidermoid tumors of the mandible. Report of 2 cases. *Cancer* 1963;16:721-726.
8. Bouquot JE, Gnepp DR, Dardick I, Hietanen JHP. Intraosseous salivary tissue: jawbone examples of choristomas, hamartomas, embryonic rests, and inflammatory entrapment: another histogenetic source for intraosseous adenocarcinoma. *Oral Surg Oral Med Oral Pathol Oral Radiol Endod* 2000;90:205-217.
9. Kochaji N, Goossens A, Bottenberg P. Central mucoepidermoid carcinoma: case report, literature review for missing and available guideline proposal for coming case reports. *Oral Oncol (extra)* 2004;40:95-105.
10. Pires FR, Paes de Almeida O, Lopes MA, Elias da Cruz Perez D, Kowalski LP. Central mucoepidermoid carcinoma of the mandible: report of four cases with long term follow up. *Int J Oral Maxillofac Surg*. 2003;32:378-382.
11. Seifert G and Sobin LH Histological typing of salivary gland tumours. In *International Classification of tumours* New York Springer-Verlag 1991.
12. Loos D. Central mucoepidermoid carcinoma of the jaw. *Dtsch Monatschr Zahnheik* 1913;31:308.
13. Pindborg JJ, Kramer IRH, Torloni H. *Histologic typing of odontogenic tumors, jaw cysts and allied lesions*. Geneva: World Health Organization, 1971, pp 35-36.
14. Waldron CA, Mustoe TA. Primary intraosseous carcinoma of the Mandible with probable origin in an odontogenic cyst. *Oral Surg Oral Med Oral Pathol* 1989;67:716-724.
15. Raut DL, Khedkar SA. Primary intraosseous mucoepidermoid carcinoma of the maxilla: a case report and review of literature. *Dentomaxillofacial Radiology* 2009;38:163-168.
16. Gingell JC, Beckerman T, Levy BA, Slinder LA. Central mucoepidermoid carcinoma. Review of the literature and report of a case associated with an apical periodontal cyst. *Oral Surg Oral Med Oral Pathol* 1984;4:436-446.
17. Waldron CA, Koh ML Central mucoepidermoid carcinoma of the jaws: report of four cases with analysis of the literature and discussion of the relationship to mucoepidermoid, sialodontogenic, and glandular odontogenic cysts. *J Oral Maxillofac Surg* 1990;48:871-877.
18. Brookstone MS, Huvos AG. Central salivary gland tumors of the maxilla and mandible: a clinicopathologic study of 11 cases with an analysis of the literature. *J Oral Maxillofac Surg*. 1992;50:229-236.
19. Martinez Madrigal F, Pineda-Daboïn K, Casiraghi O, Luna MA. Salivary gland tumors of the mandible. *Ann Diag Pathol* 2000;4:347-353.