



Ectopic molar in the maxillary antrum presenting as recurrent maxillary sinusitis and halitosis

*Gbotolorun OM, **Ogwumba CU, **Adeyemi M,
*** Effiom OA, **Alawode AO

*Department of Oral & Maxillofacial Surgery, Faculty of Dental Sciences, College of Medicine;

**Department of Oral & Maxillofacial Surgery, Lagos University Teaching Hospital;

*** Department of Oral Pathology & Oral Biology, Faculty of Dental Sciences,
College of Medicine, University of Lagos.

Correspondence: Gbotolorun OM

Email: lekangbotol@yahoo.co.uk

Abstract

Ectopic eruption of teeth into the maxillary sinus is a rare phenomenon and can present in a variety of ways such as chronic or recurrent sinusitis, sepsis, nasolacrimal duct obstruction, headaches, osteomeatal complex and halitosis. However most cases are asymptomatic and are only discovered by chance especially through panoramic radiography. A case of a 29 year old female who presented with a 5 year history of chronic sinusitis and halitosis radiography who had done several periapical x-rays and had used various antibiotics to no effect. An ectopic tooth was discovered through an OPG and with removal of the tooth all symptoms subsided.

Introduction

Ectopic teeth are those located in regions other than the alveolar arch, they may be supernumerary, deciduous or permanent. Although ectopic eruption of a tooth into jawbone is not an uncommon entity, ectopic eruption into other sites are infrequent^(1,2). Reported sites of ectopic include the maxillary sinus, palate, mandibular condyle, coronoid process, orbit, nasal cavity or through the skin⁽¹⁻³⁾. Although the aetiology of eruption of a tooth into the maxillary sinus is unclear, ectopic placement or irregularities in the migration of teeth or tooth buds may occur due to both genetic and environmental factors. Suggested causes of ectopic eruption into the maxillary sinus include cleft palate, displacement of teeth by trauma or cyst, infection, genetic factors, crowding and dense bone are the suspected clinical conditions^(1,3).

Most cases of ectopic teeth in the maxillary sinus are asymptomatic and are usually found during routine clinical and radiographic investigations, especially with the increased use of panoramic x-rays⁽⁴⁾. Previous symptomatic cases in the literature of presented mostly with chronic sinusitis other symptoms included haemoptysis, epiphora which resulted from lacrimal duct obstruction and facial swelling when occurring in association with a dentigerous cysts^(1,4,5-7). We present a case of tooth in the antrum with chronic sinusitis and halitosis of about 5 years duration which was initially misdiagnosed due to lack of widespread use of panoramic x-rays in our environment.

Case Report

A case of a 29yrs old female who presented at the Dental Clinic, Lagos University Teaching Hospital (LUTH), on 8th day of May 2011 on account of pain in upper right quadrant, discharge of foul smelling fluid into her mouth and halitosis of 5 years duration. All these symptoms occurred intermittent during the period. The current episode started 1 month prior to her presenting in the clinic. The associated pain is throbbing in nature, spontaneous, severe,

continuous and aggravated by cold drinks. The pain she claimed radiated to the eye, ear and right part of the nose, in the present episode there was also a purulent discharge from right nostril and swelling of the region.

She had previously been to several private clinics where she claimed that repeated periapical x-rays were taken which showed no associated lesion in the periapical area associated with the discharging sinus in the oral cavity. She had however been placed on several antibiotics in the past in these clinics including Augmentin, Amoxycilline, metronidazole, gentamycin and lincomycin. She was referred to LUTH by the last private clinic she visited.

On examination the patient at presentation did not seem to be in any obvious distress, was not pale, anicteric, afebrile to touch and not dehydrated. There was also no obvious facial asymmetry but there was a swelling intraorally in the upper right buccal sulcus with a discharging sinus posterior to 17. Soft tissue examination revealed tenderness in buccal sulcus and gingiva adjacent to 15 and 16 on palpation. The 18, 38, 44 and 46 teeth were missing. There were no carious teeth and no teeth were tender to percussion.

A new periapical x-ray was taken (patient did not present with any of her previous x-rays) which did not reveal any pathology in the periapical region around the apices of the 15, 16 and 17. However, a panoramic x-ray (**Figure 1**) revealed a molar tooth (possibly the 18 which was missing in the oral cavity) close to the roof of the right antrum. A diagnosis of chronic sinusitis secondary to foreign body impaction was made.

Routine hematological investigations were done and all were within normal range. The foreign body in the right maxillary antrum was removed via Caldwell-Luc approach (**Figure 2**) under General Anesthesia. Intra-operatively the foreign body and about 15mls of muco-purulent fluid was removed from the antrum. Patient was placed on Tabs Metronidazole 400mg, IM Ceftriazone 1g Tabs Vit C 100mg, and Ephedrine nasal drops. There were no fresh complaints when she was reviewed at the clinic 10 days postoperatively.

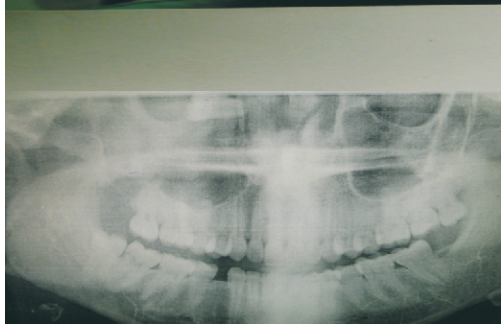


Figure 1: Panoramic X-ray showing molar tooth close to the roof of right antrum

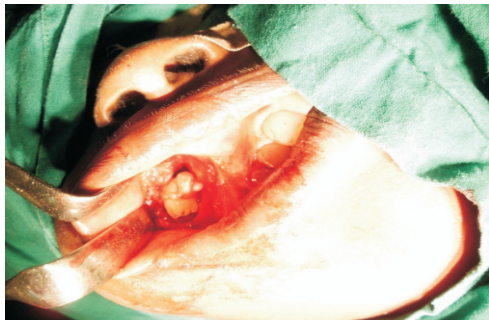

Figure 2: Caldwell Lac approach to remove tooth from the right maxillary antrum

Discussion

Ectopic tooth in the maxillary sinus is a rare phenomenon^(2,8). A recent review by Lamb et al identified only 35 reported cases of this phenomenon in English language medical literature from 1927 to 2008⁽⁹⁾. The etiology of ectopic eruption has not yet been completely clarified, but many theories have been suggested, including trauma, infection, developmental anomalies and pathologic conditions, such as dentigerous cysts⁽¹⁻⁷⁾. Walsh and Smith⁽¹⁰⁾ reported an ectopic second molar attached to the maxillary antrum and their possible etiologic factor was ankylosis subsequent to injury sustained during infancy. However except for a few cases, the aetiology is unclear in most of the reported cases⁽²⁾. In the present case the aetiology is also unclear. The proximity of the ectopic tooth to certain walls of the antrum have been attributed to certain causes. In a series reported by Baykul et al⁽²⁾ ectopic teeth that were related to the floor, lateral and posterior walls of the antrum were associated with dental and skeletal anomalies which presented with crowding. They purported that the proximity of these teeth to the dento-alveolar bone might suggest they resulted from overcrowding of the arch. In the present case the ectopic tooth was almost at the roof of the antrum and there was no associated crowding in the arch of the patient.

Ectopic tooth in the maxillary sinus may be permanent, deciduous or supernumerary. Di Felice and Lombardi⁽⁸⁾ reported an ectopic third molar as an extremely rare case, but a search of the literature reveals that the ectopic upper third molars in the maxillary sinus are the most commonly

reported teeth in the literature⁽⁷⁾. A maxillary third molar is also the ectopic tooth in our case.

Ectopic teeth in the maxillary sinus are usually discovered on routine clinical or radiographic examinations, as most of the cases were asymptomatic^(2,4,7). The most common symptom associated with ectopic teeth in the antrum is chronic sinusitis^(1,2,7). This is thought to result from osteomeatal complex obstruction^(2,7). Other associated symptoms include haemoptysis, epiphora which results from lacrimal duct obstruction and facial swelling. Repeated headaches and intermittent purulent nasal discharge have also been reported⁽²⁻⁸⁾. Our case presented with chronic sinusitis associated with intermittent nasal discharge and halitosis. Although halitosis is not a common symptom of ectopic tooth in maxillary sinus, our case also presented with a discharging sinus into the mouth and the halitosis might not have been unconnected with this finding.

In a review of literature by Lamb et al⁽⁹⁾ they reported that the age at discovery of ectopic teeth in the maxillary antrum ranged from 3 to 62 years, with slightly more than half discovered before adulthood. The reason for the finding they claimed was because the entity often discovered by chance during clinical or radiographic examination. Sixty percent of patients were males, and a similar number of cases were found in the right and left nasal cavities.

Ectopic teeth in the maxillary sinus are radiopaque and therefore they are easily diagnosed radiographically. Plain film imaging of the maxillary sinus such as Water's view, panoramic radiography and plain skull radiography are simple and relatively inexpensive methods, which can be used in daily practice⁽⁴⁾. CT scans and lateral cephalometric x-rays also play a role in the definitive diagnosis, the panoramic x-ray has however been reported to be the most important diagnostic x-ray because the shape of the teeth is easily seen on them⁽⁴⁾. In the present case definitive diagnosis was not made in the dental centres the patient visited because only intraoral periapical x-rays were available in the clinics. Extraoral radiographs including panoramic x-rays are not easily assessable except in very few private clinics and teaching hospitals in our environment and this contributed immensely to the late diagnosis of our case. Localisation of the tooth before surgical removal is often necessary. CT scans are reported to be the goal standard in this role⁽¹¹⁾. Combinations of panoramic x-rays and lateral cephalometric x-rays have also been used successfully for this role in literature⁽²⁾. A true lateral of skull and a panoramic x-ray were used in our case for localisation of the tooth in the antrum.

The most often reported surgical treatment of ectopic tooth in the antrum reported in the literature is removal via the Caldwell-Luc procedure this was also the method used in our case. Another method of removal reported in literature is via transnasal endoscopy which is reported to be associated with much less surgical morbidity⁽¹²⁾. This approach is however not routinely done in our environment.

Conclusion

We report a case of a 29 year old female who presented with a 5 year history of chronic sinusitis, intermittent nasal discharge and halitosis who had had done several periapical x-rays and had used various antibiotics to no effect. An ectopic tooth was discovered in the antrum through a panoramic and with removal of the tooth all symptoms subsided.



References

1. Erkmén NO, İmez S, Nerci M. Supernumerary tooth in the maxillary sinus. *Aust Dent J* 1998; 43: 385-386.
2. Baykul T, Dogru H, Yasan H, Aksoy M. Clinical impact of ectopic teeth in the maxillary sinus. *Auris Nasus Larynx* 2006; 33: 277-281.
3. Elonga S, Palaniappan SP. Ectopic tooth in the roof of the maxillary sinus. *Ear Nose Throat J* 1991; 70: 365-366.
4. Tadahiko S, Yumoto E. Quantification of X-ray opacity of the maxillary sinus in the Water's view. *Auris Nasus Larynx* 1997; 24: 289-297.
5. Goh YH. Ectopic eruption of maxillary molar tooth: An unusual cause of recurrent sinusitis. *Singapore Med J* 2001; 42: 80-81.
6. Alexandrakis G, Hubbell RN and Aitken PA. Nasolacrimal Duct Obstruction Secondary to Ectopic Teeth. *Ophthalmology* 2000; 107: 189-192.
7. Saleem T, Khalid U, Hameed A, Ghaffar S. Supernumerary, ectopic tooth in the maxillary antrum presenting with recurrent haemoptysis. *Head & Face Med* 2010; 6: 26-29.
8. DiFelice R, Lombardi T. Ectopic third molar in the maxillary sinus. *Aust Dent J* 1995; 40: 236-237.
9. Lamb JF, Husein OF, Spiess AC. Ectopic molar in the maxillary sinus precipitating a mucocele: a case report and literature review. *Ear Nose Throat J* 2009, 88: E6-E11.
10. Walsh MR, Smith NHH. An ectopic maxillary second molar. *Aust Dent J* 1980; 25: 69-72.
11. Konen E, Faibel M, Kleinbaum Y, Wolf M, Lusky A, Hoffman C, et al. The value of the occipitomental (Water's) view in diagnosis of sinusitis: A comparative study with computed tomography. *Clin Radiol* 2000; 55: 856-860.
12. Hasbini AS, Hadi U, Ghafari J. Endoscopic removal of an ectopic third molar obstructing the osteomeatal complex. *Ear Nose Throat J* 2001, 80: 667-670.